

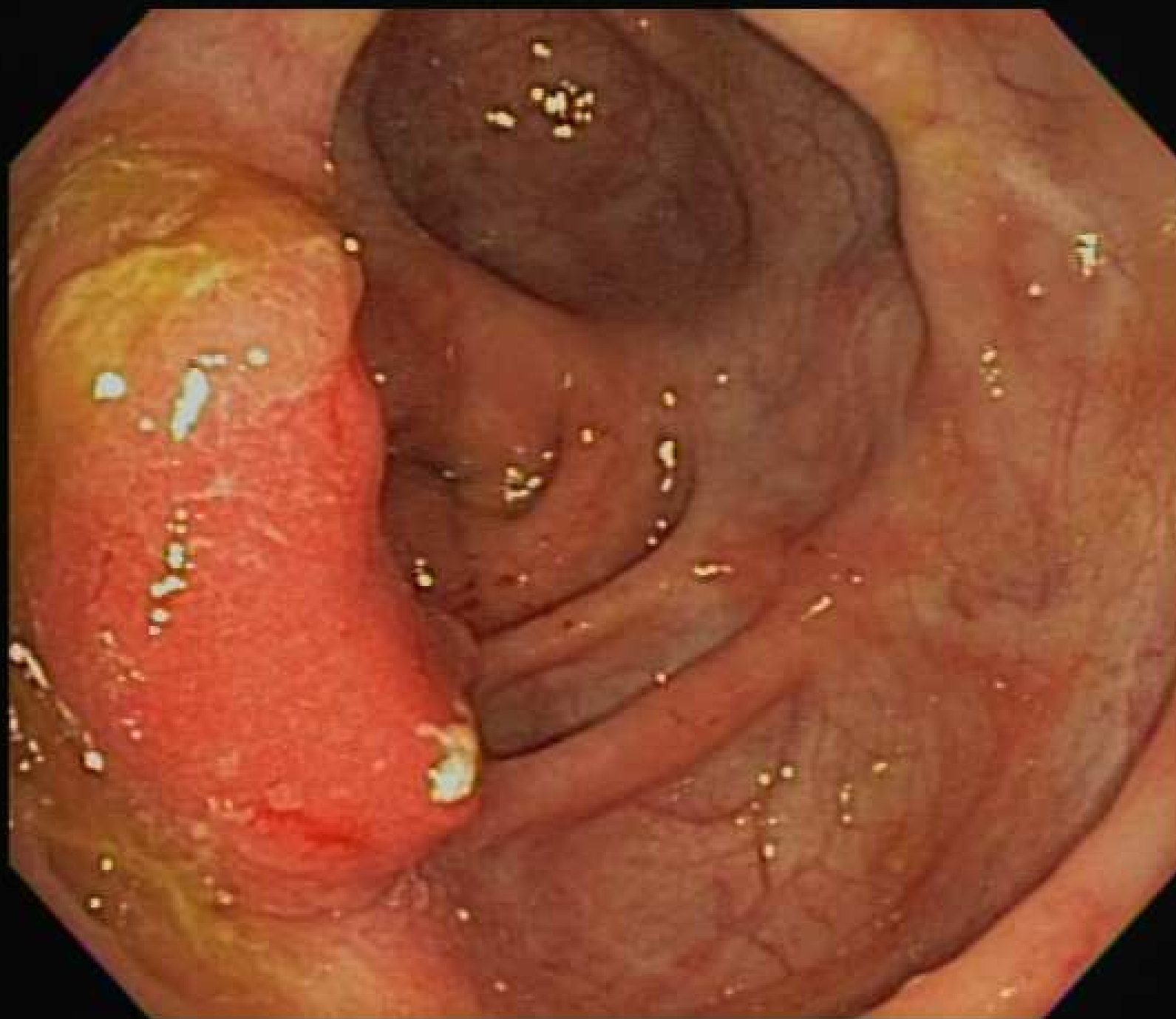
16º ENCONTRO DO NÚCLEO DE ESPECIALIDADES

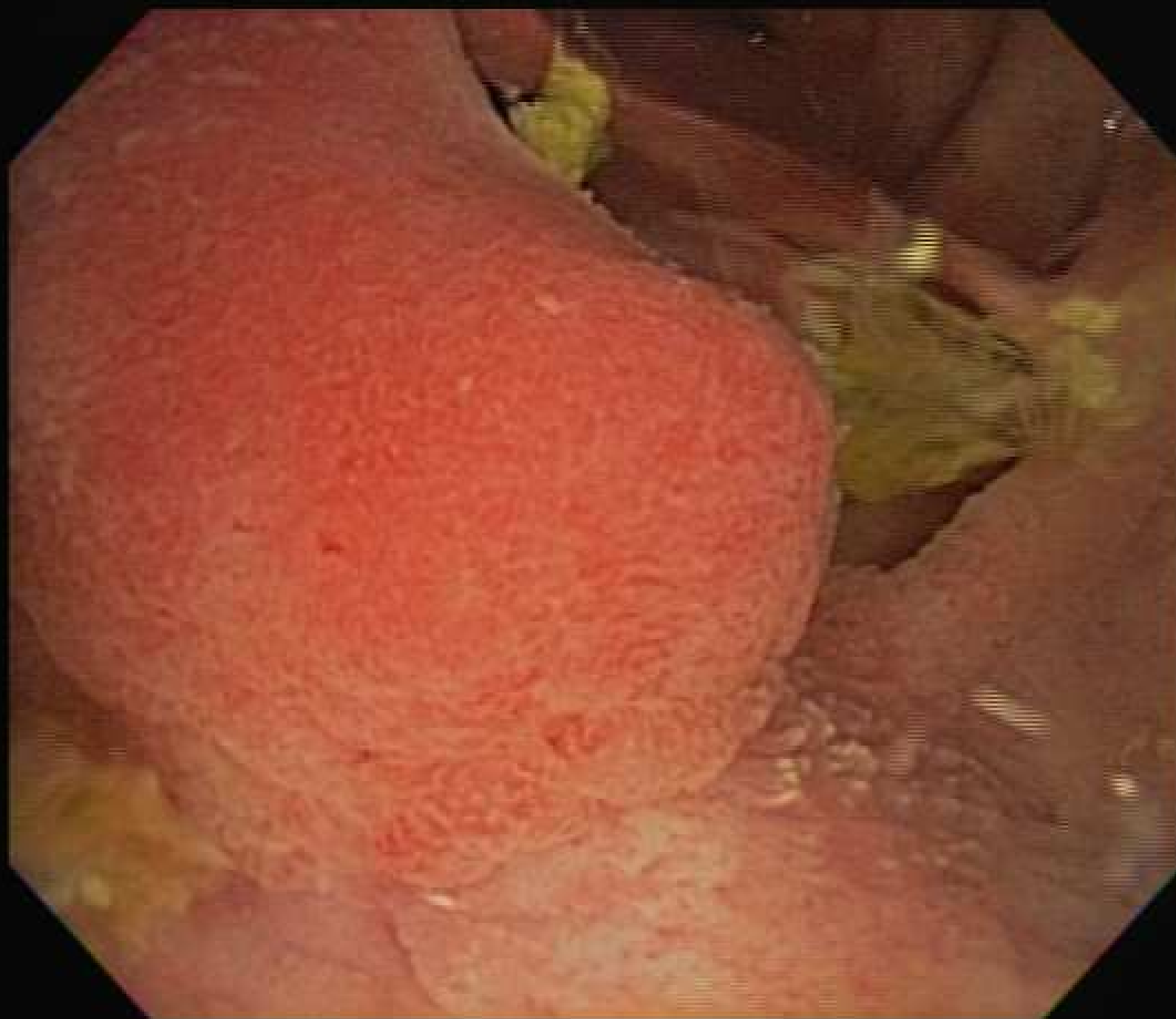
Área de Patologia Gastrointestinal

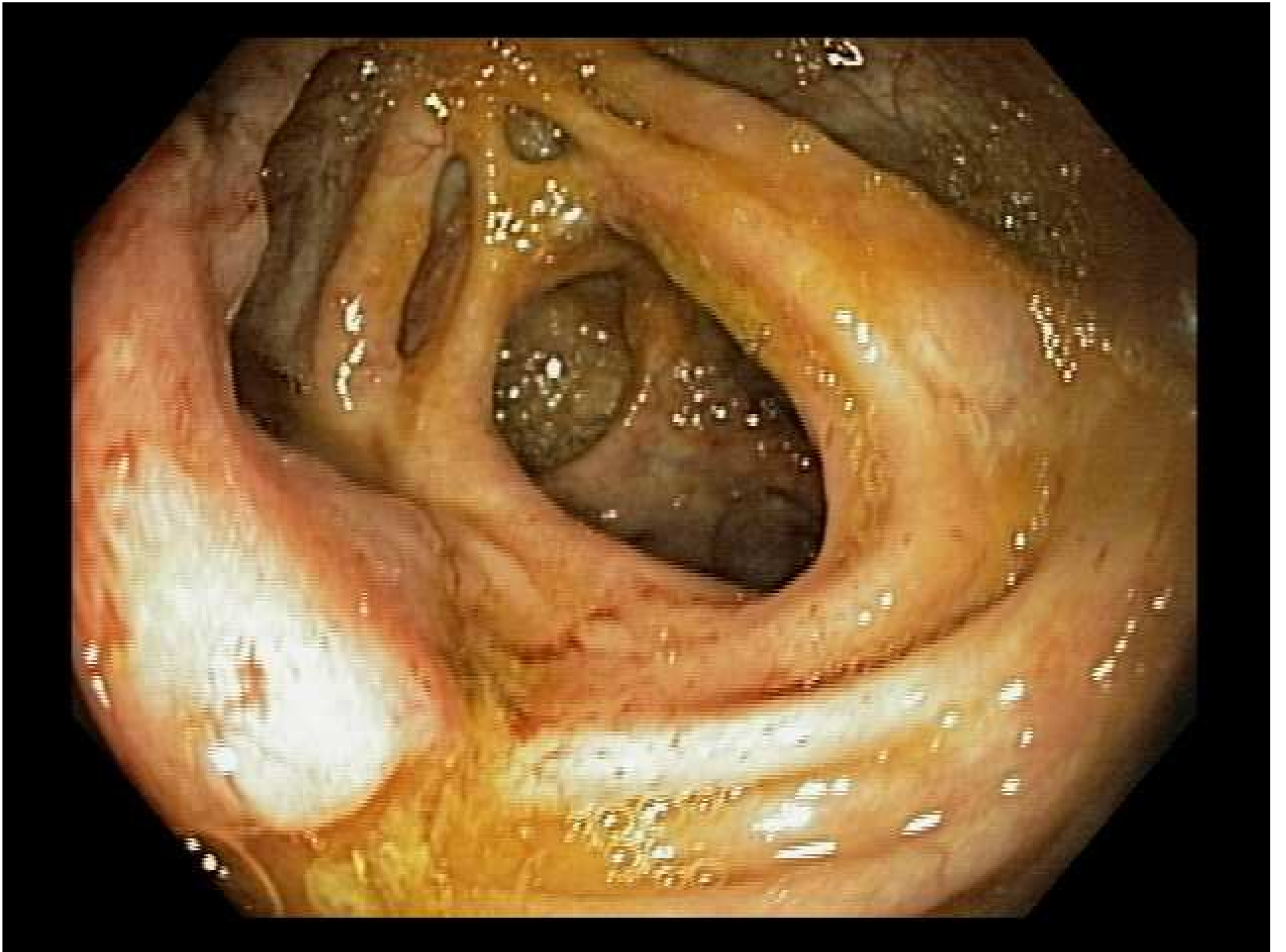
Gil Pena

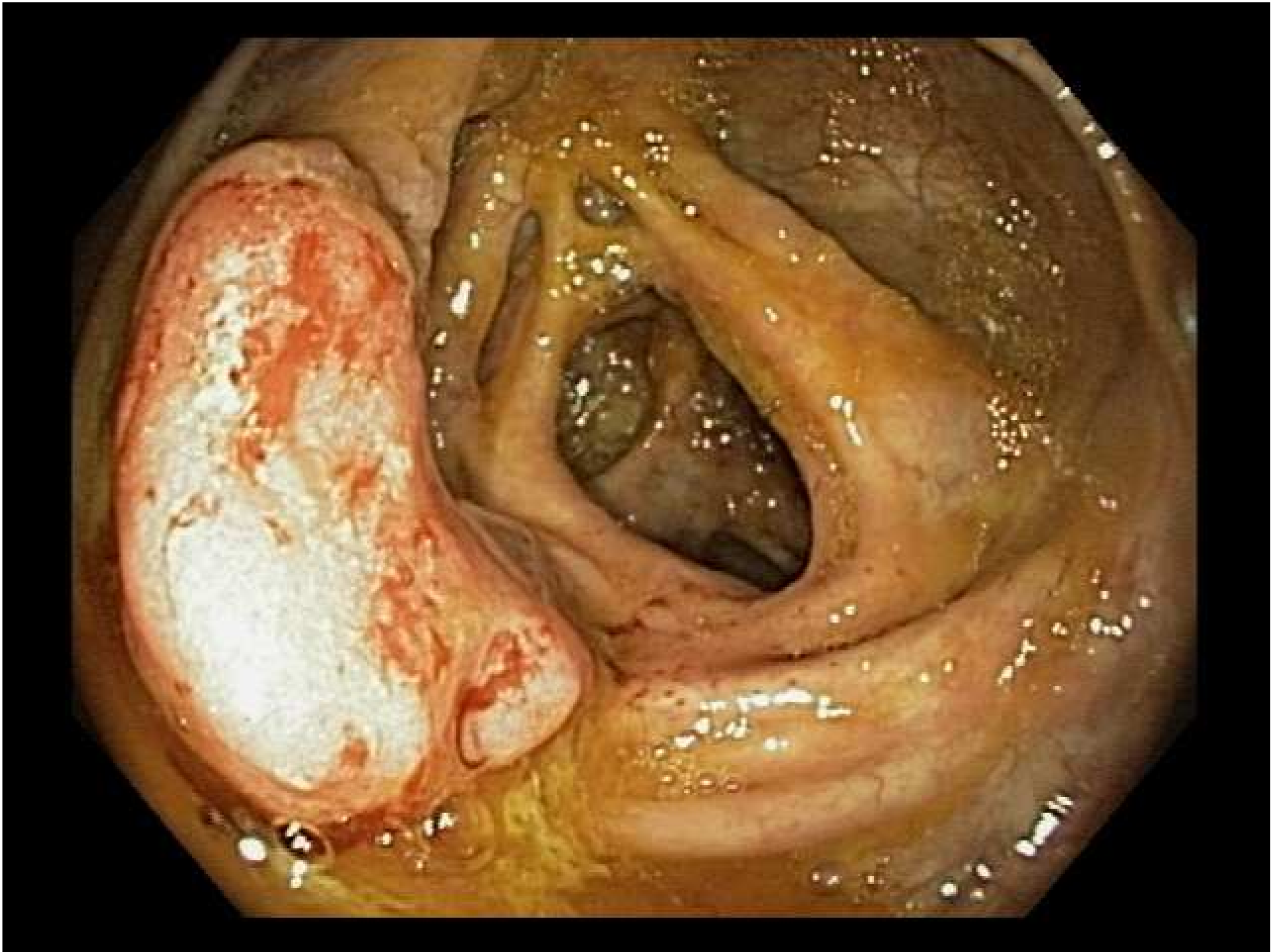
gilpena@gold.com.br

Masculino, 65 anos.
Biópsias colonoscópicas de lesão
polipóide de ascendente.
Retocolite ulcerativa. Pancolite .

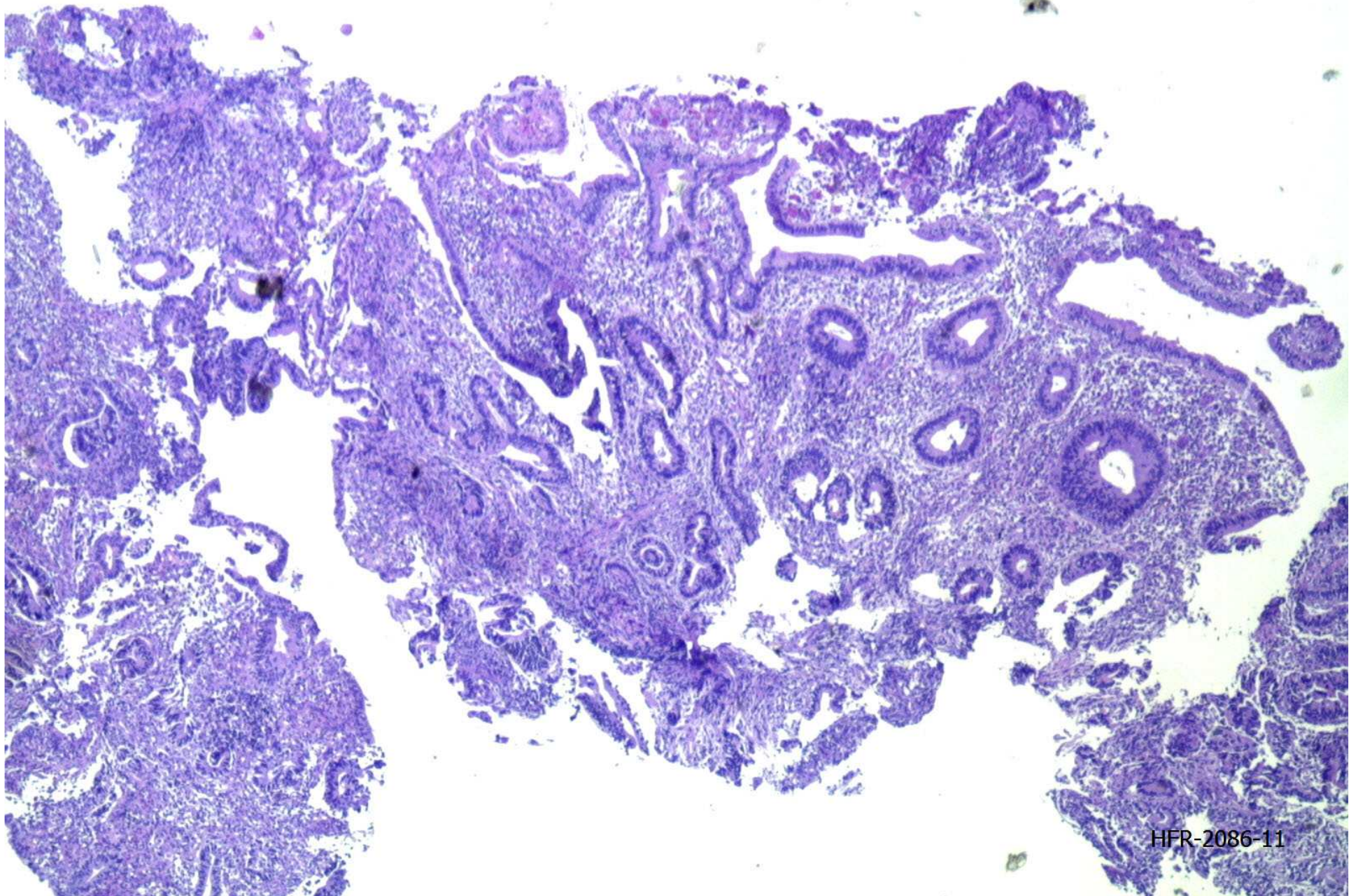






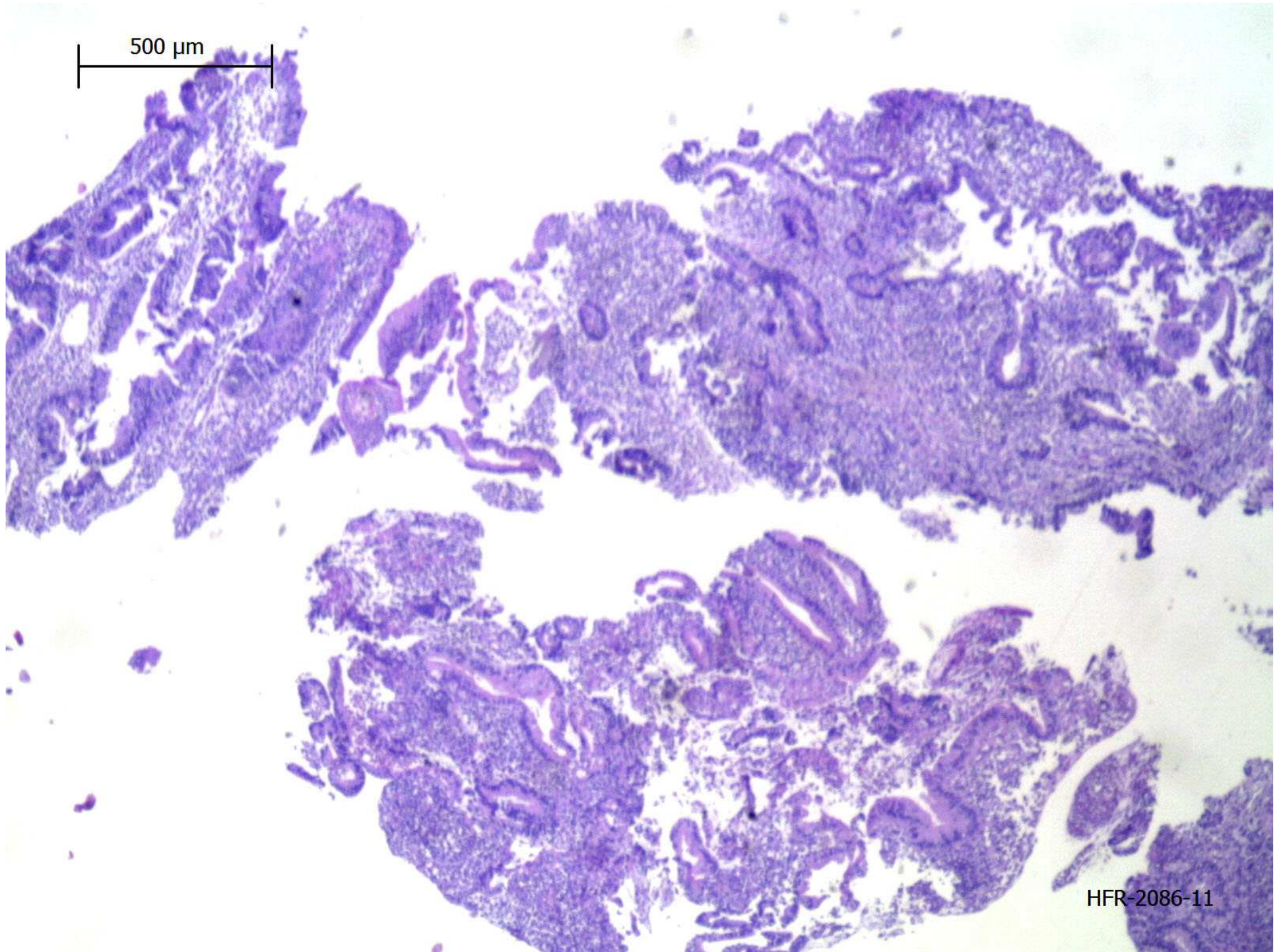


500 μ m



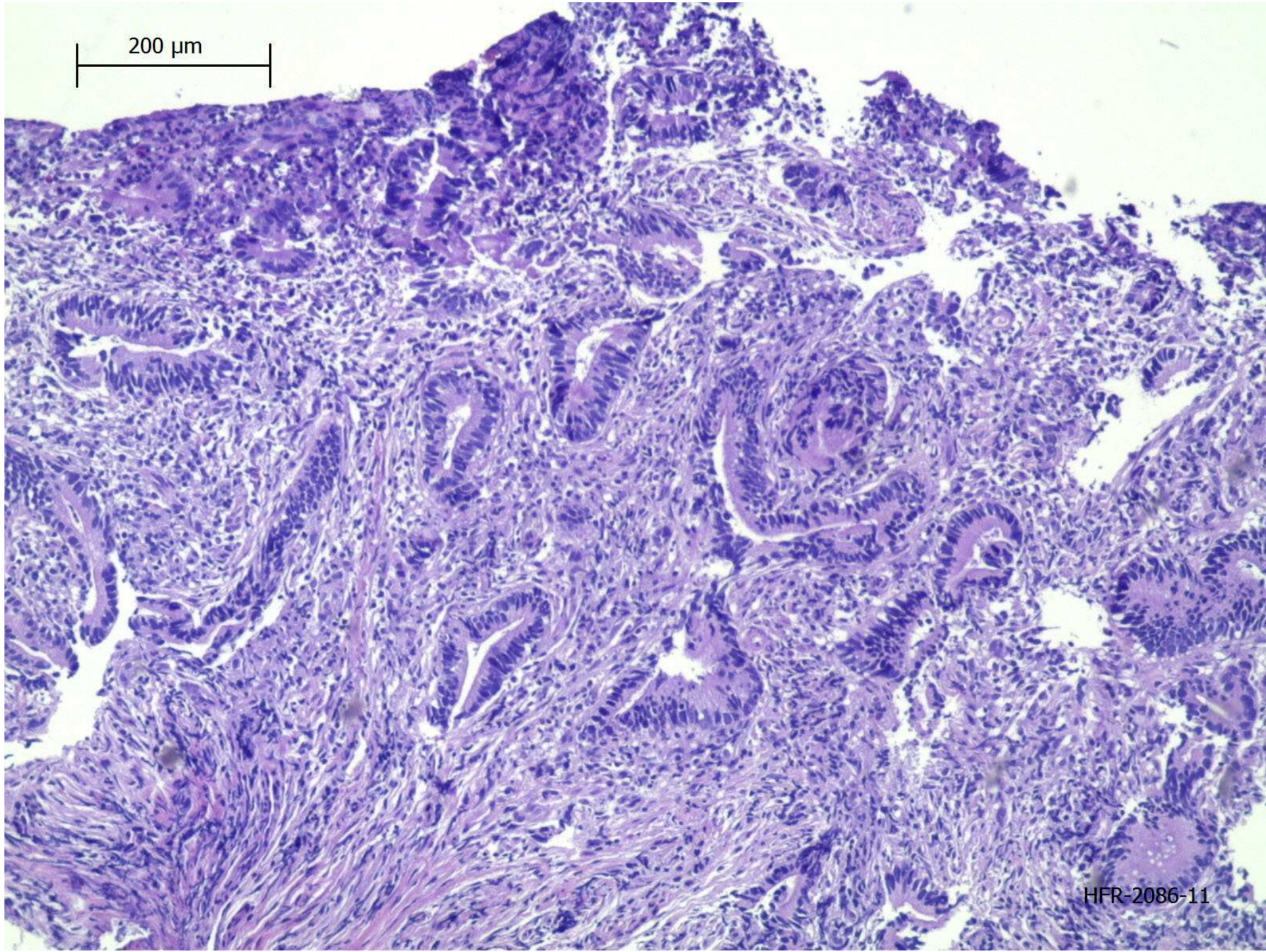
HFR-2086-11

500 μ m

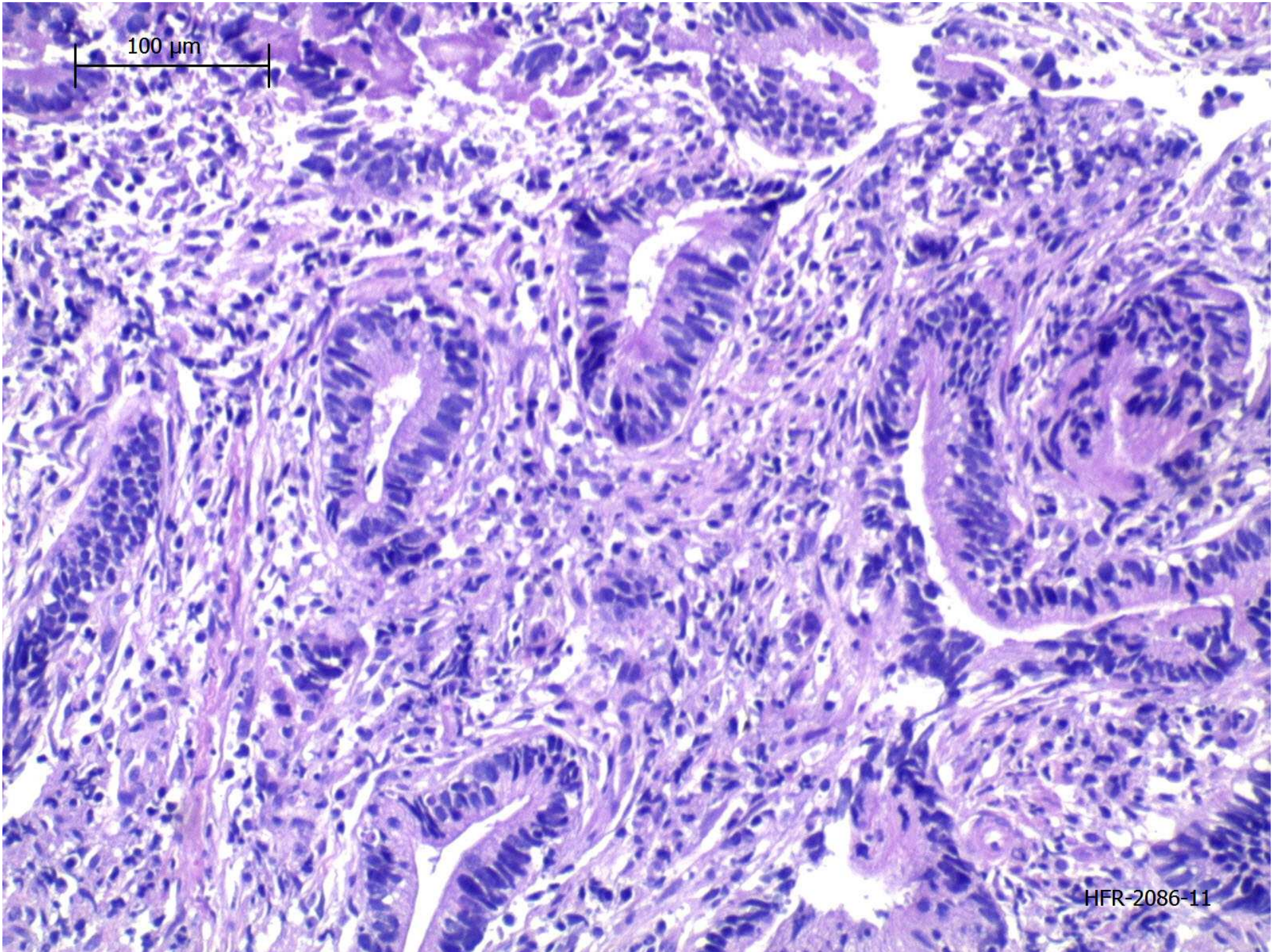


HFR-2086-11

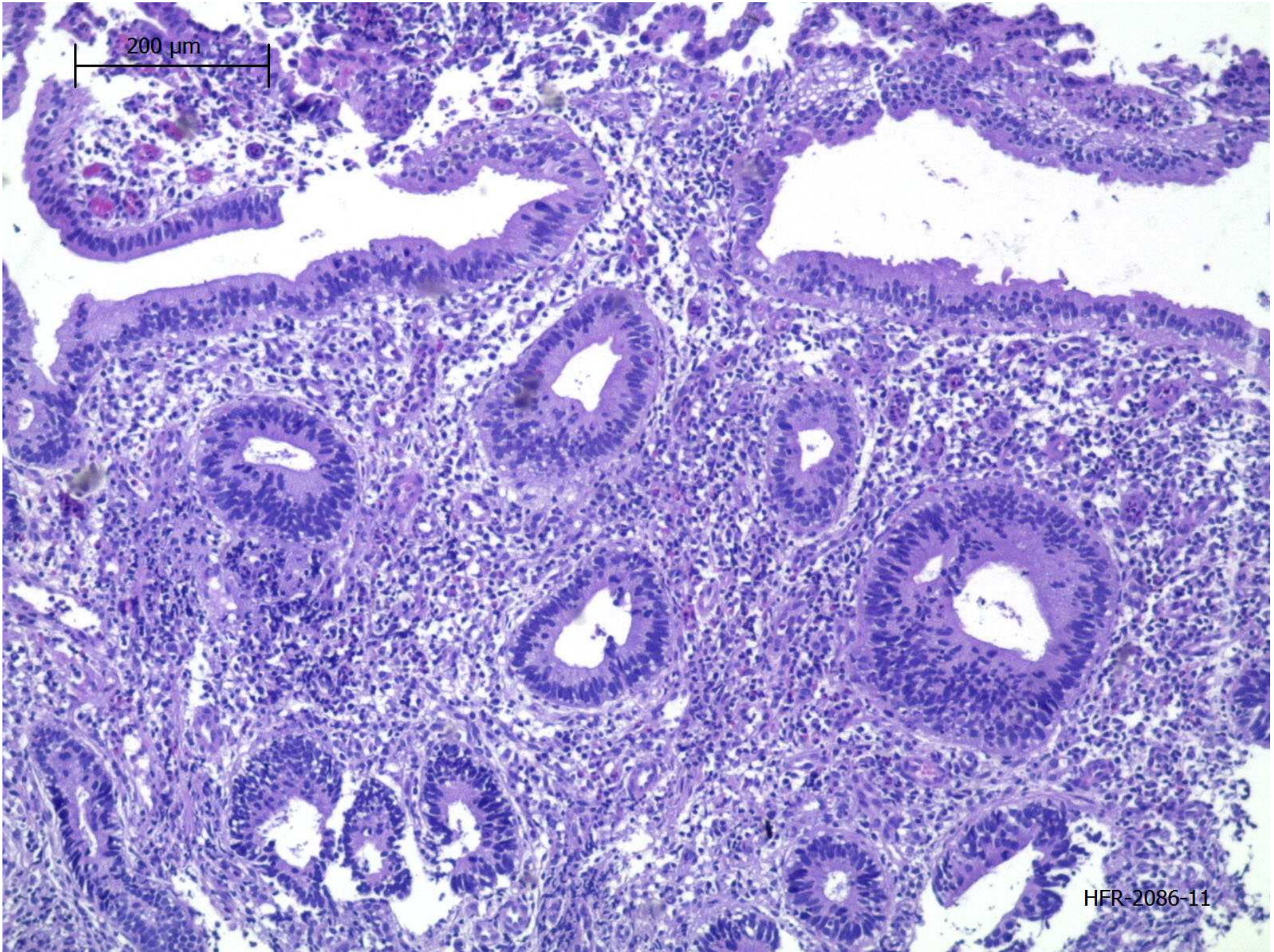
200 μ m



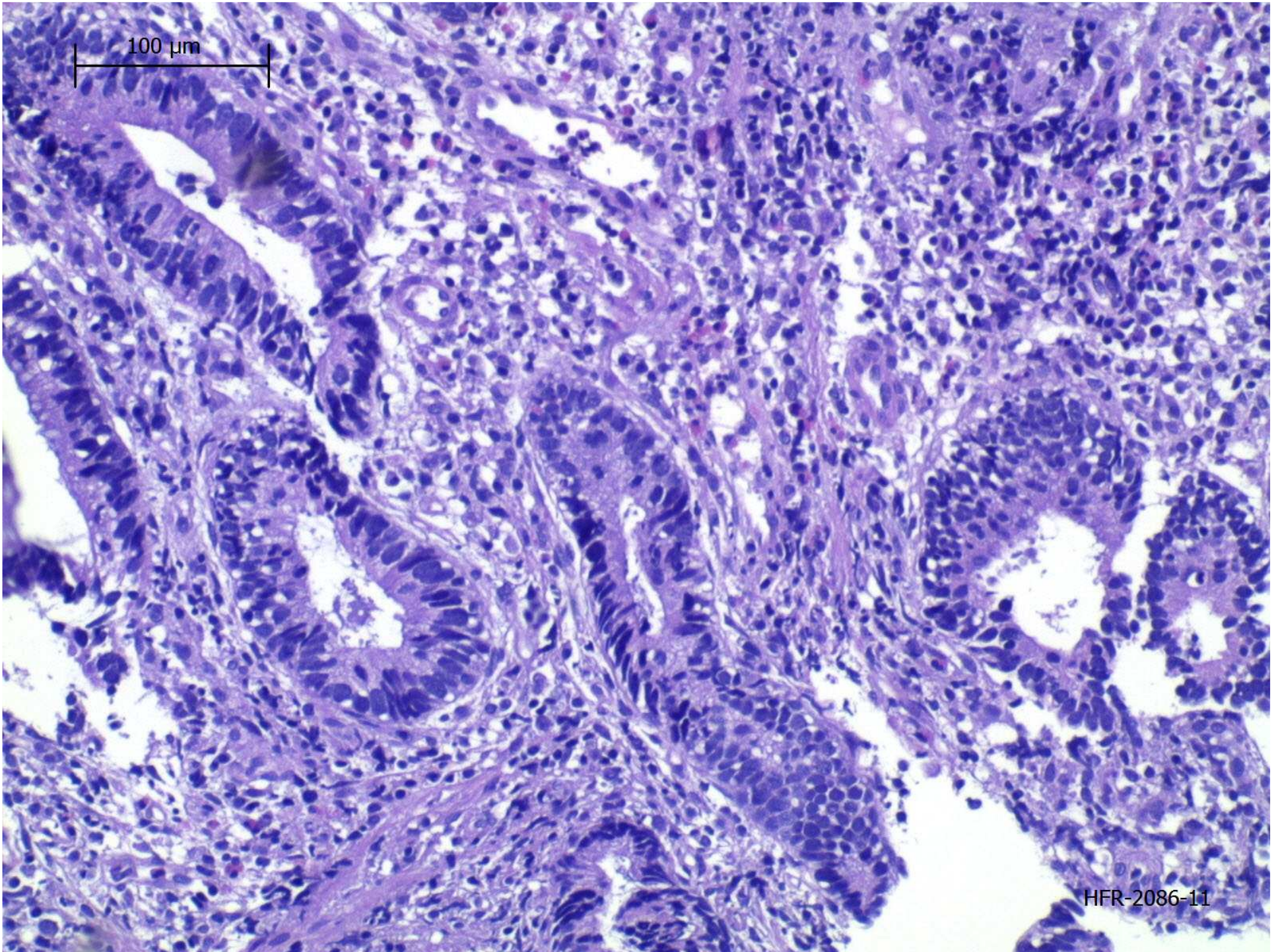
HFR-2086-11

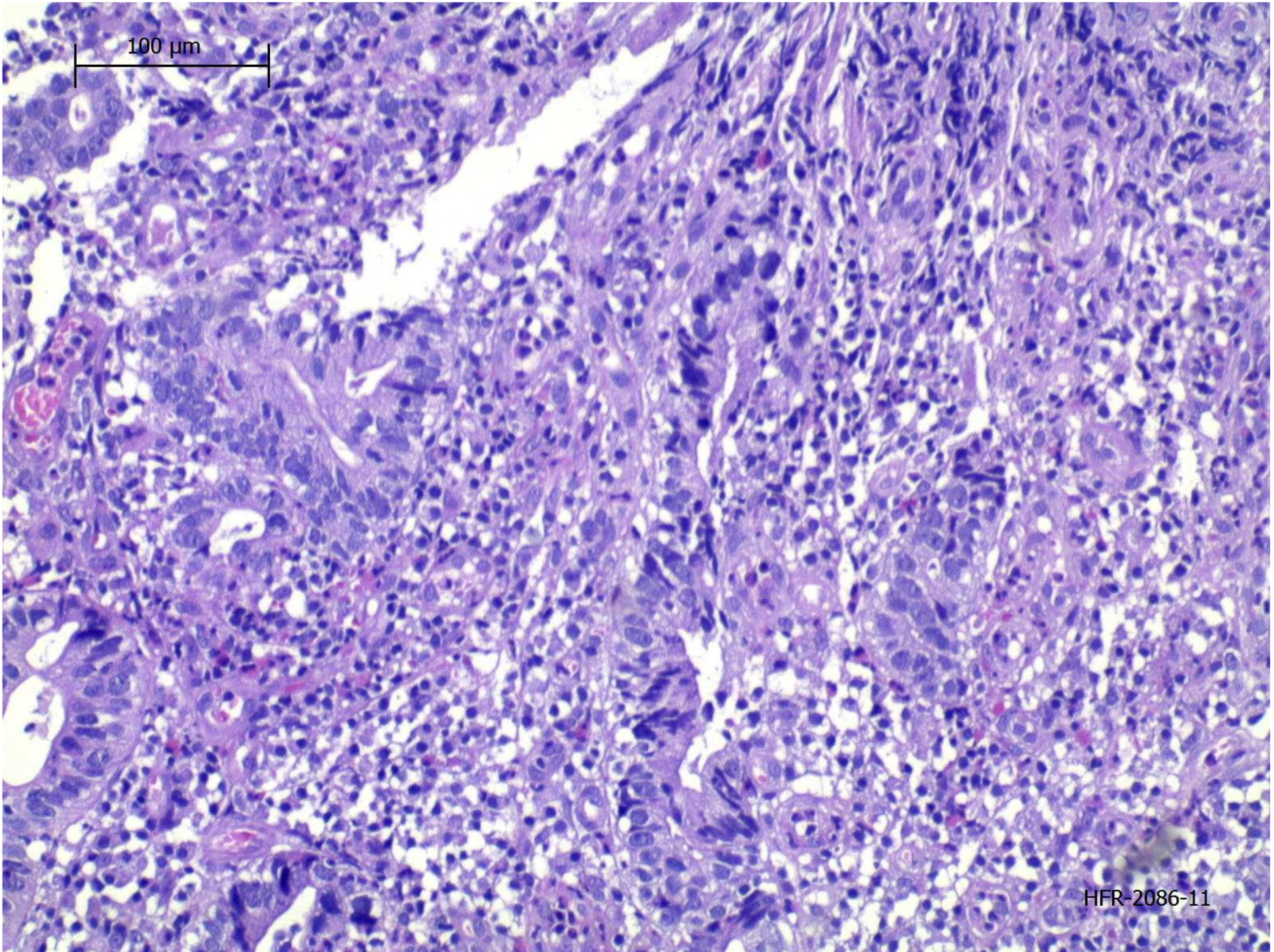


HFR-2086-11

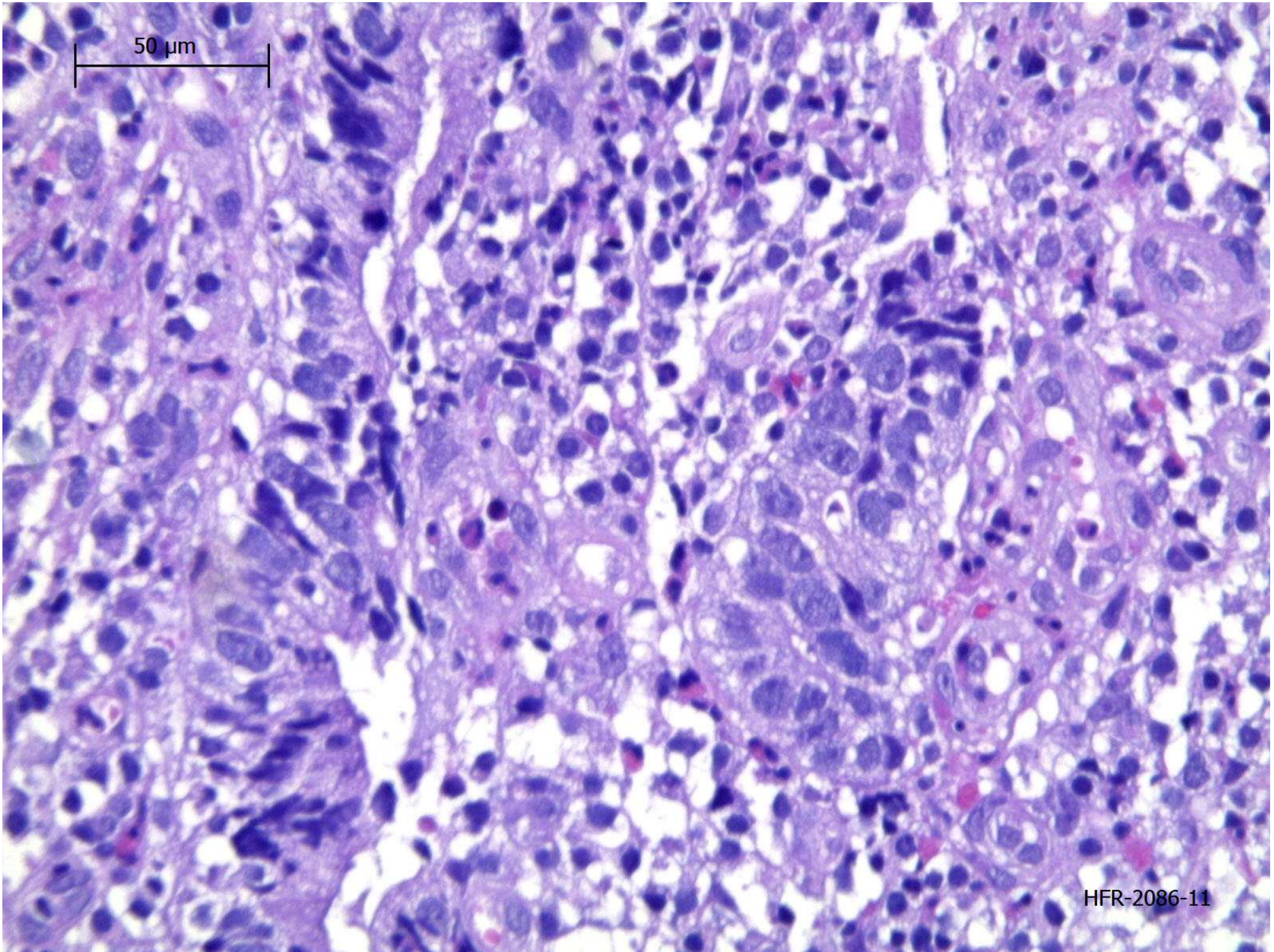


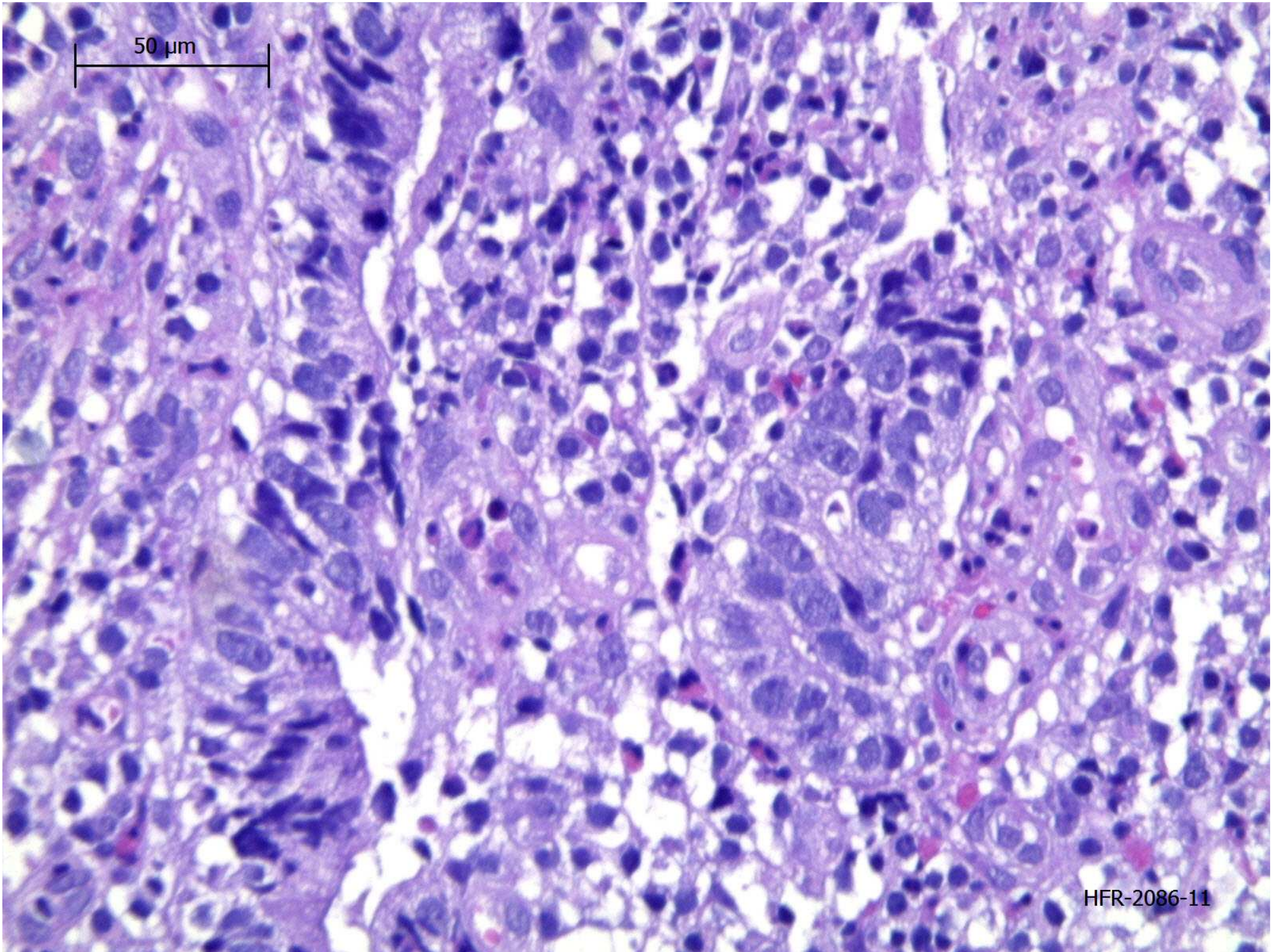
HFR-2086-11





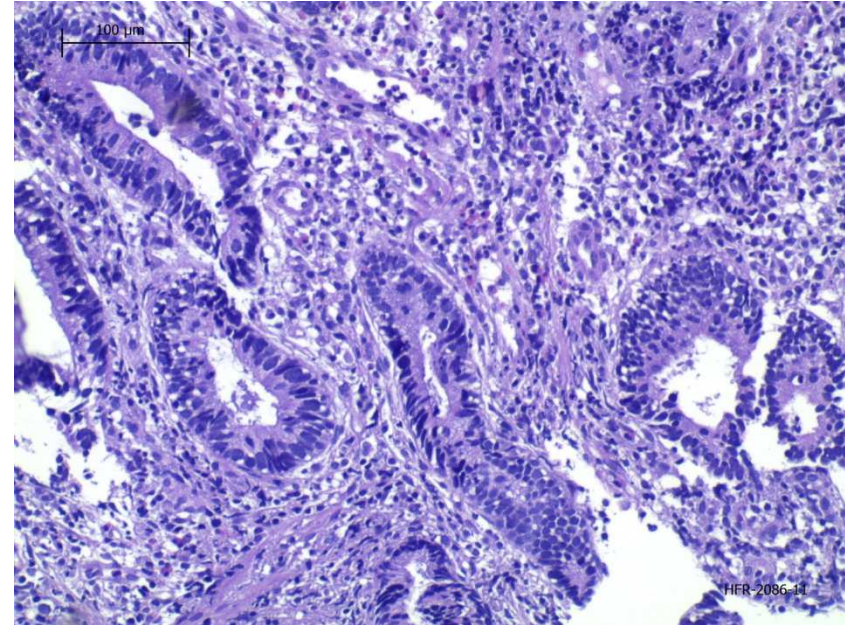
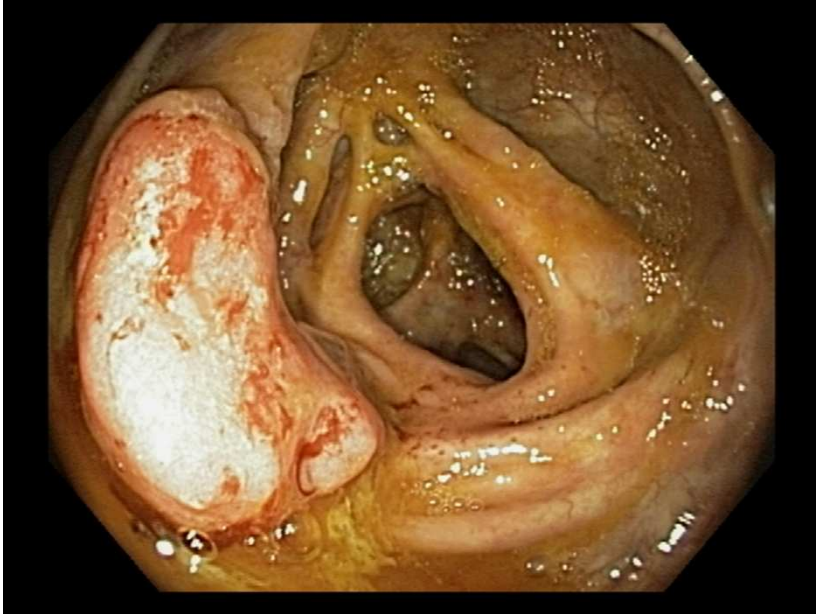
HFR-2086-11





HFR-2086-11

DIAGNÓSTICO...



“Lesão ou massa” associada a “displasia”

DALM

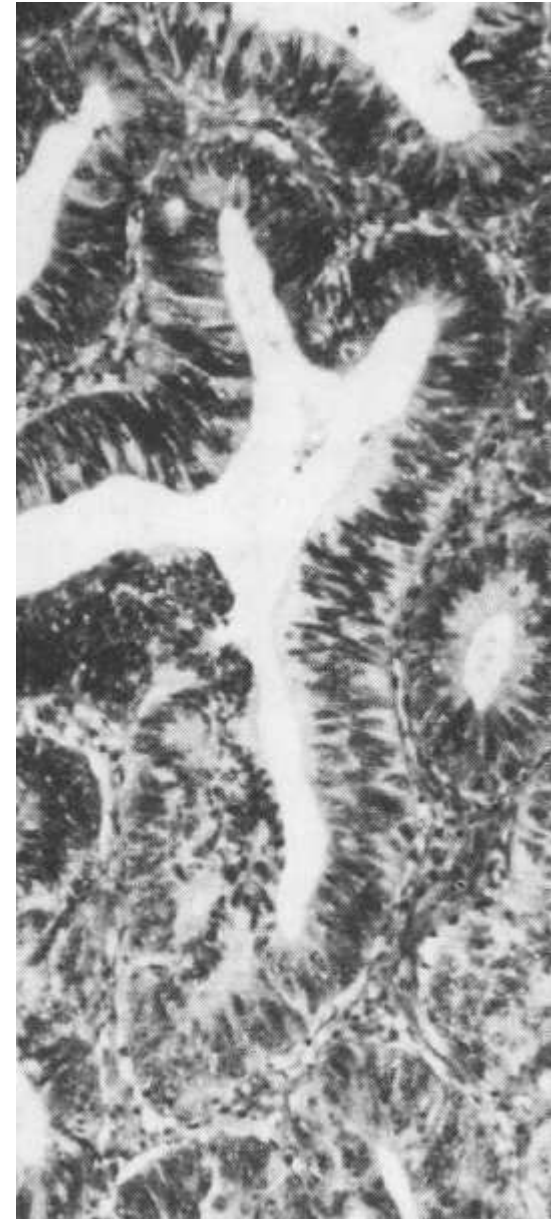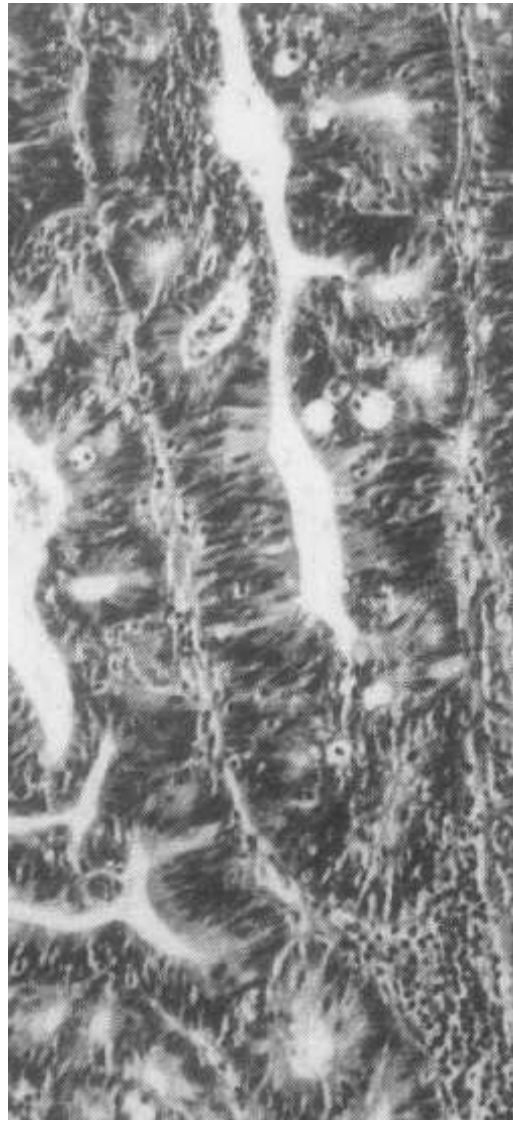
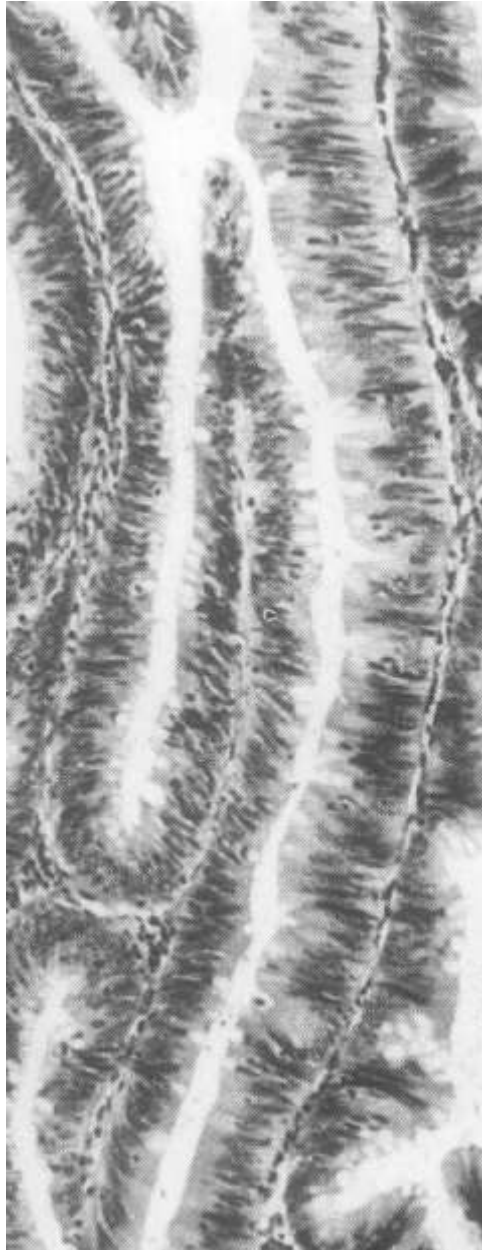
Dysplasia associated mass or lesion

A caracterização da lesão ou massa associada a displasia (DALM) requer a estreita correlação entre o quadro histológico (de alteração epitelial displásica) e os achados endoscópicos, em contexto de retocolite ulcerativa idiopática.

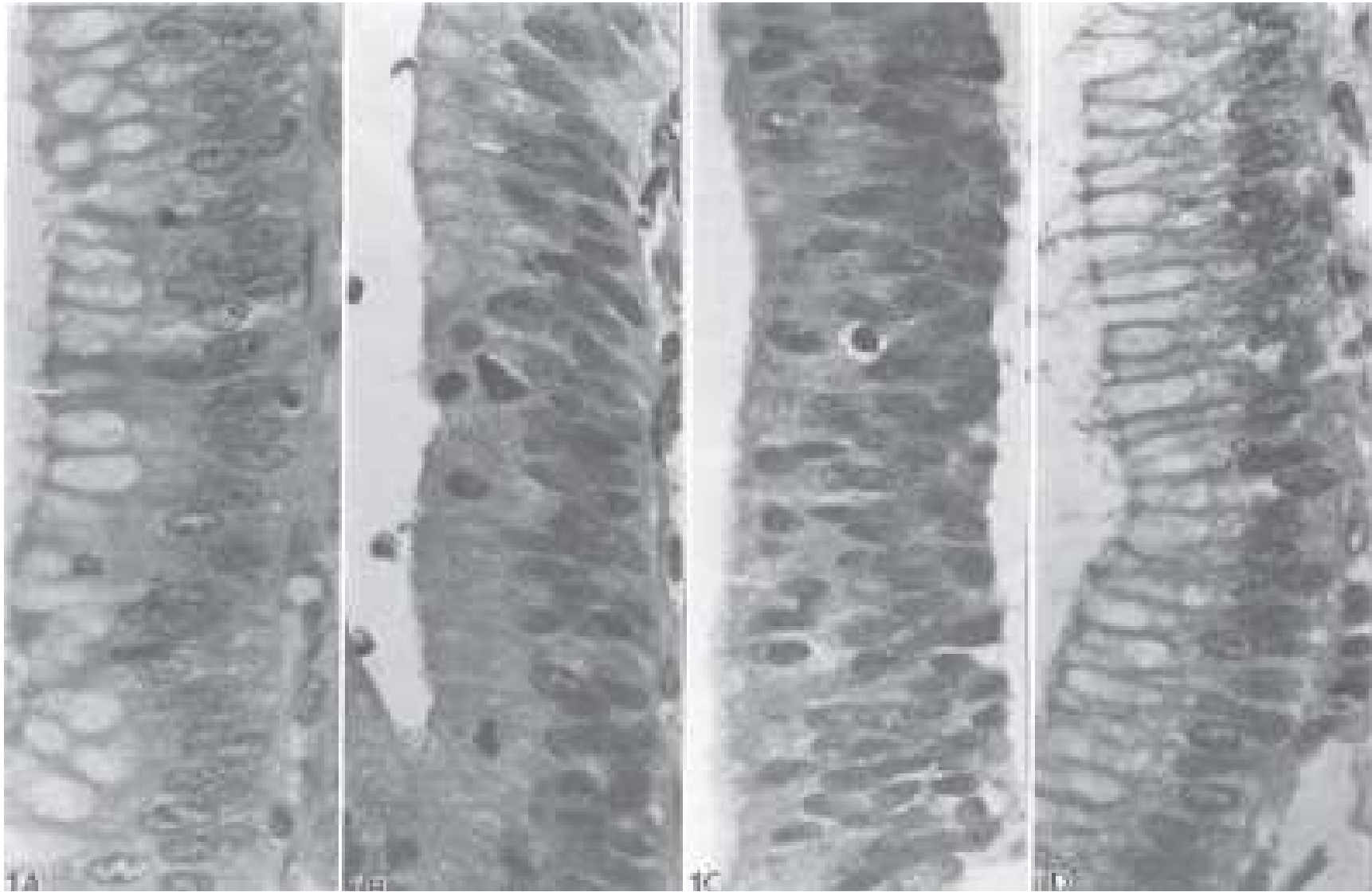
Displasia na retocolite ulcerativa

- Negativo para displasia
- Indefinido para displasia
- Positivo para displasia
 - Baixo grau
 - Alto grau

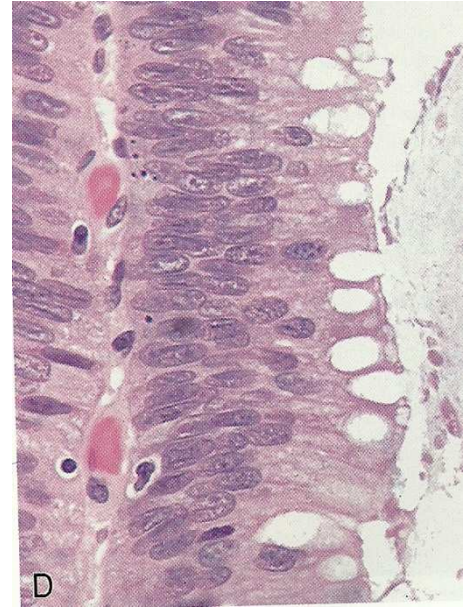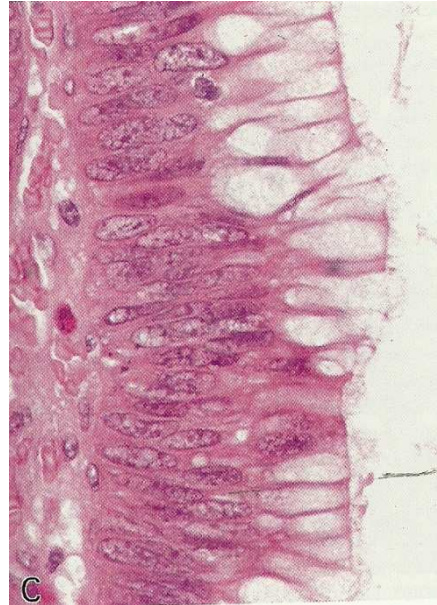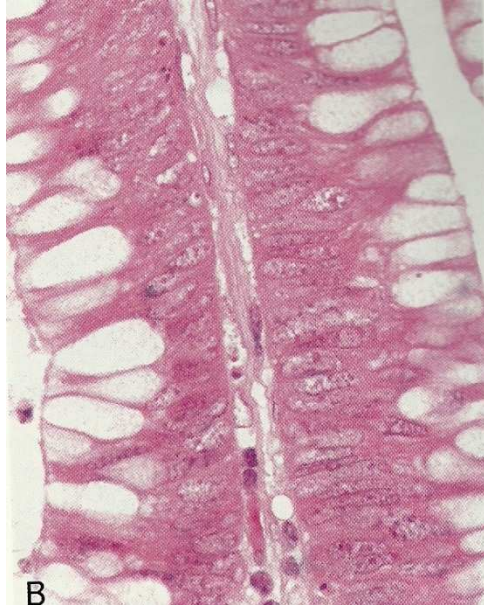
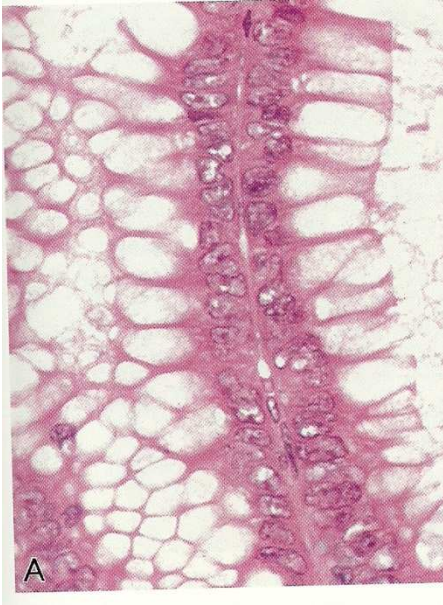
F KONISHI, BC MORSON



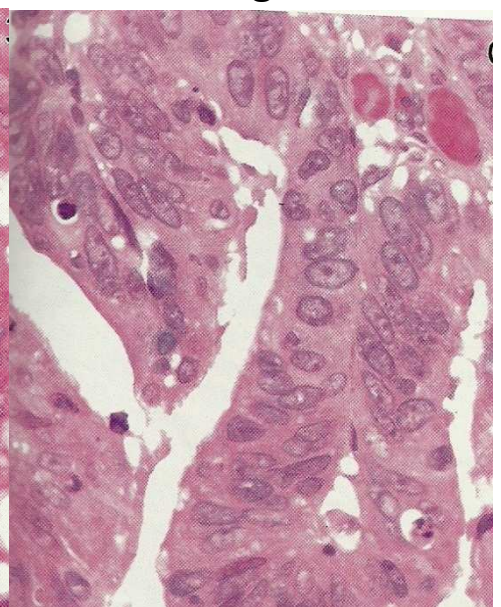
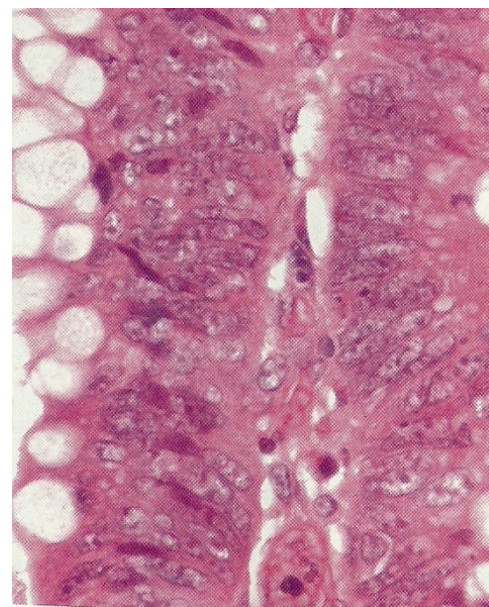
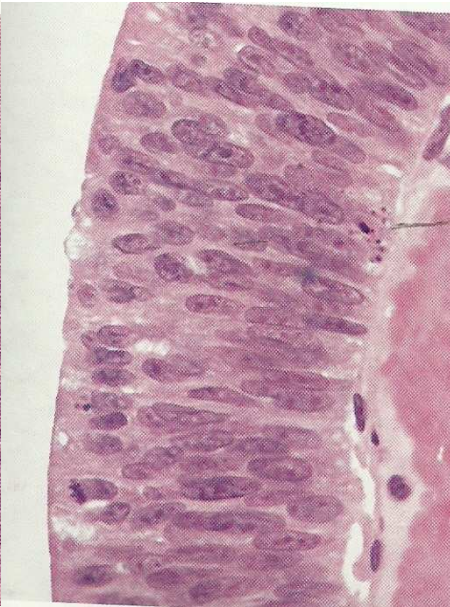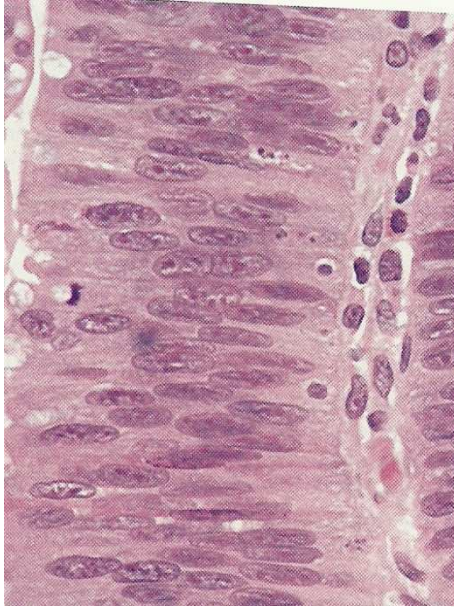
J Clin Pathol 1982;35:830-841



Blackstone et al. (1981) *Gastroenterology*, 80 (2): 366-74



Baixo grau <math>< 2/3</math>



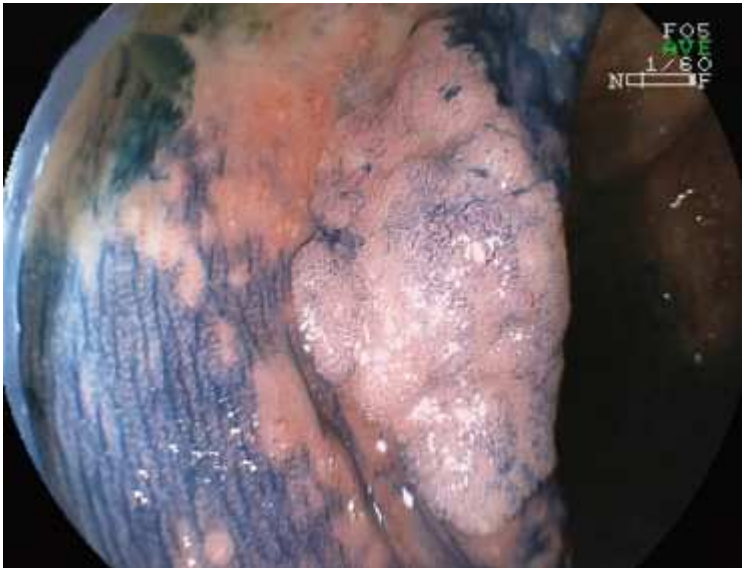
Alto grau >math> 2/3</math>

Displasia na retocolite ulcerativa

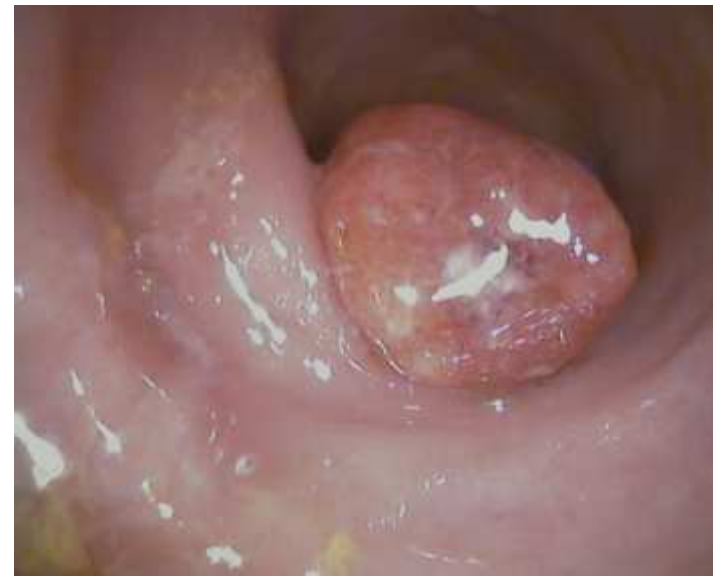- Fatores de risco
 - Extensão e duração da doença
 - Colangite esclerosante
 - A partir do 7-8 anos de doença, acompanhamento colonoscópico anual
 - Incidência crescente de displasia
 - 5% aos 10 anos de doença
 - 25% aos 20 anos de doença
 - Risco de carcinoma sobe 1 a 2% por ano depois de 10 anos de doença

DALM - Blackstone et al. (1981)

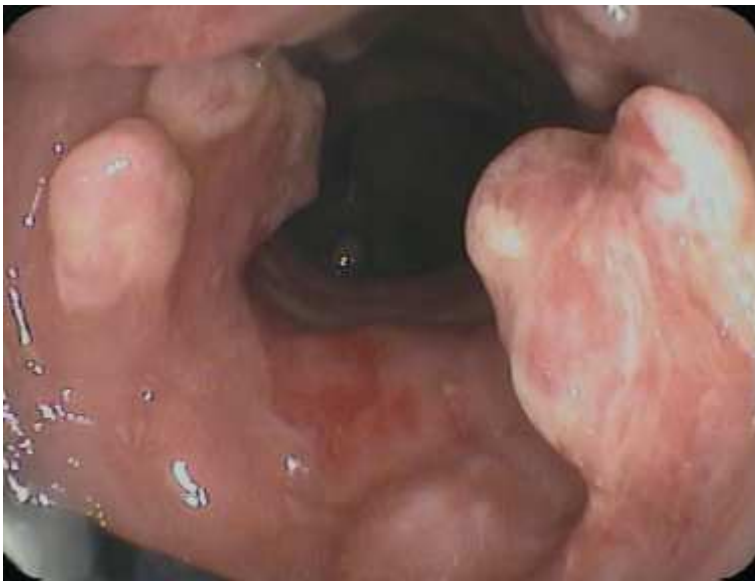
- 12/112 – Pacientes colite ulcerativa extensa ou total, prolongada (>7a.) -
- 12 casos DALM
 - Todos >10 a., máximo 37 anos
 - 10 casos com pancolite
 - Massa polipóide (5 casos), lesões em placa (2 casos), múltiplos pólipos sésseis (5 casos)
 - 7 casos com adenocarcinoma infiltrante
 - 5/5 casos com massa polipóide
- 27 casos com displasia “plana”
 - 1 caso com adenocarcinoma



DALM



Lesão adenoma-símile



Pseudo-pólipos

DALM

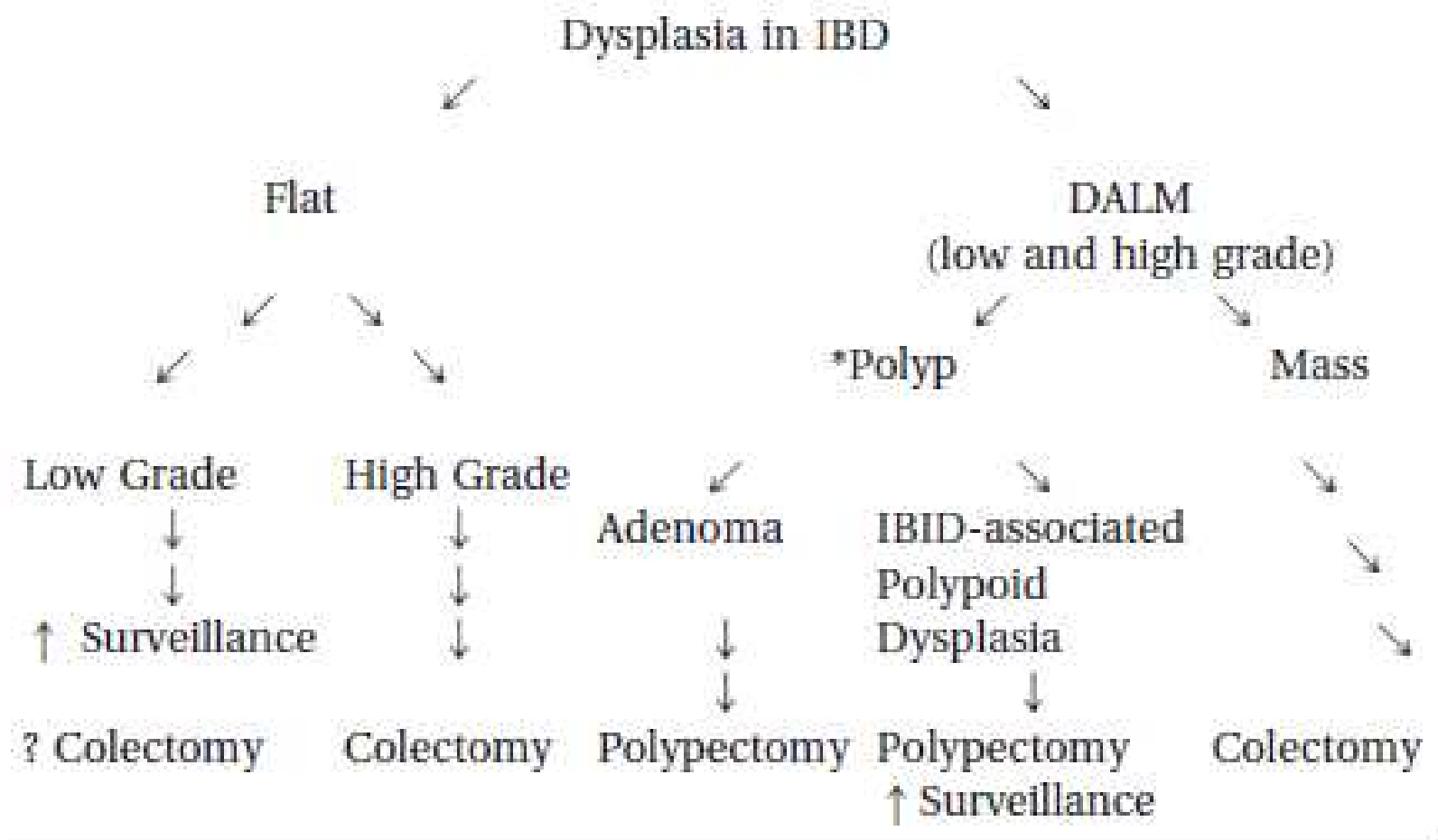
Adenoma-símile

- > 60 anos (mais velhos)
- Doença subtotal
- Quiescente
- Curta duração (<10 anos)
- Área não doente (colon dir)
- Displasia plana ≈ ausente
- Não viloso
- LOH 3P-
- LOH 16P-

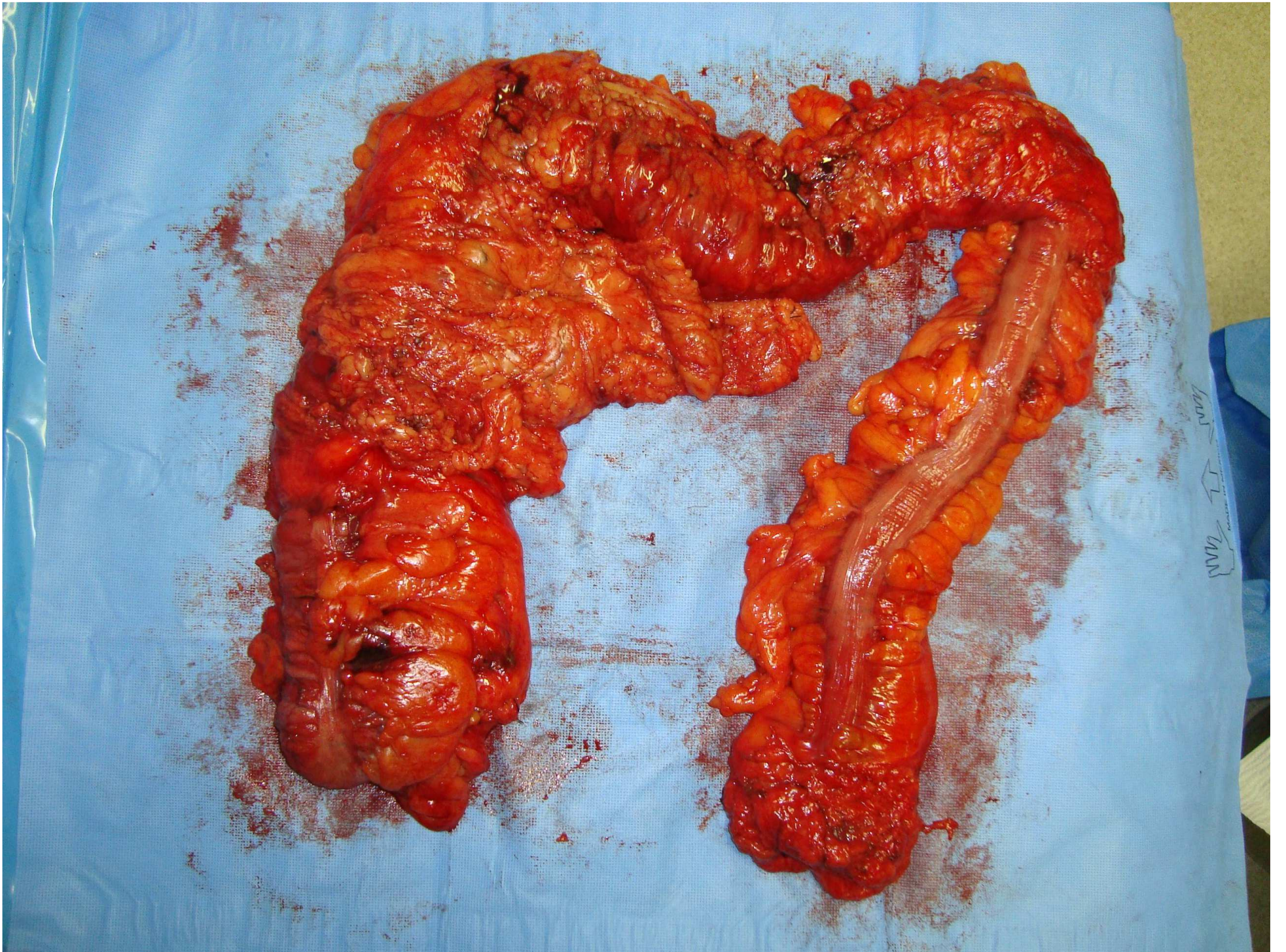
Displasia polipóide

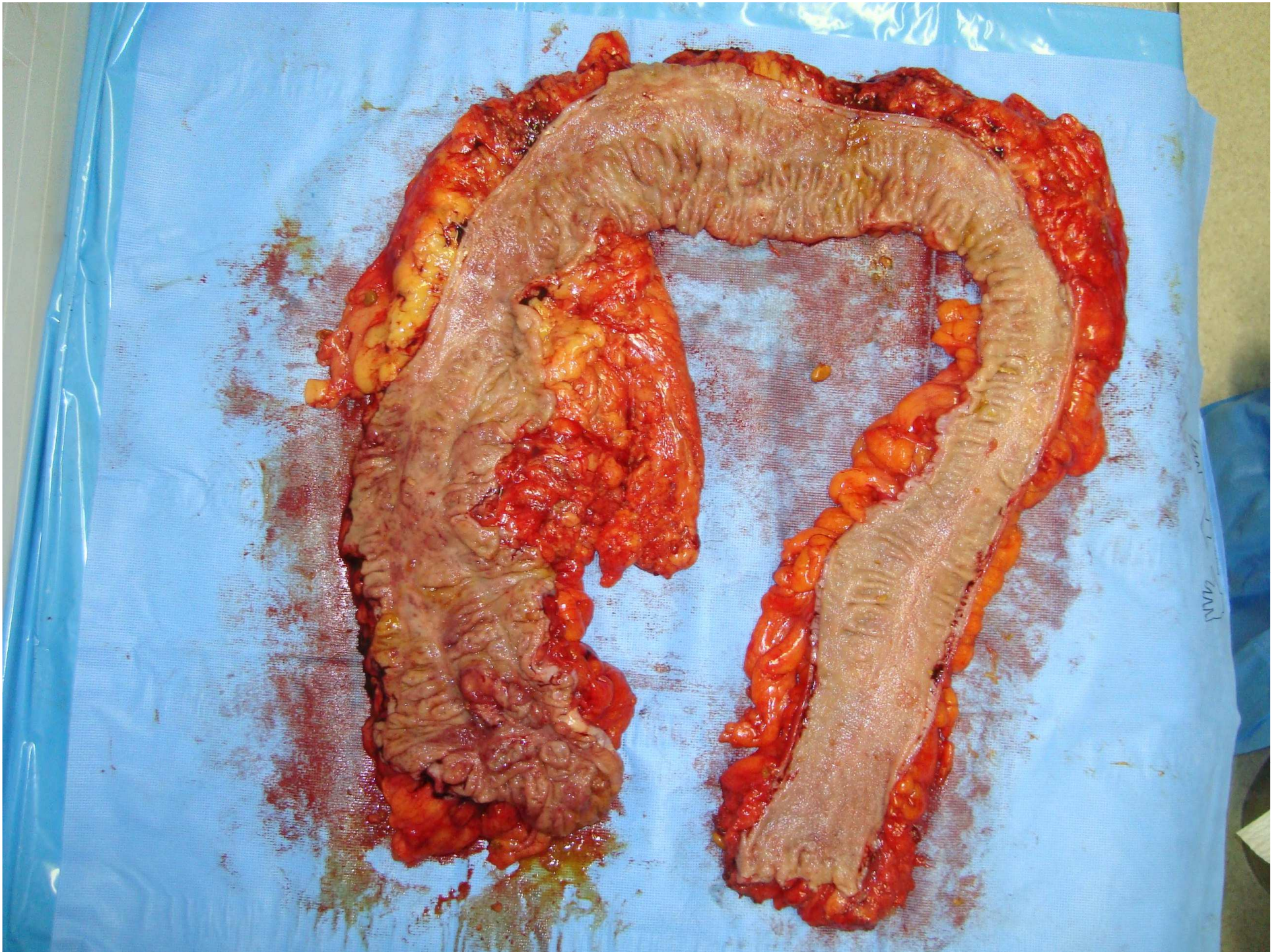- < 50 anos (mais jovens)
- Pancolite
- Doença ativa
- Longa duração (> 11 anos)
- Área inflamada (colon esq)
- Displasia plana ≈ presente
- Ocasionalmente viloso
- LOH 3P
- LOH 16P

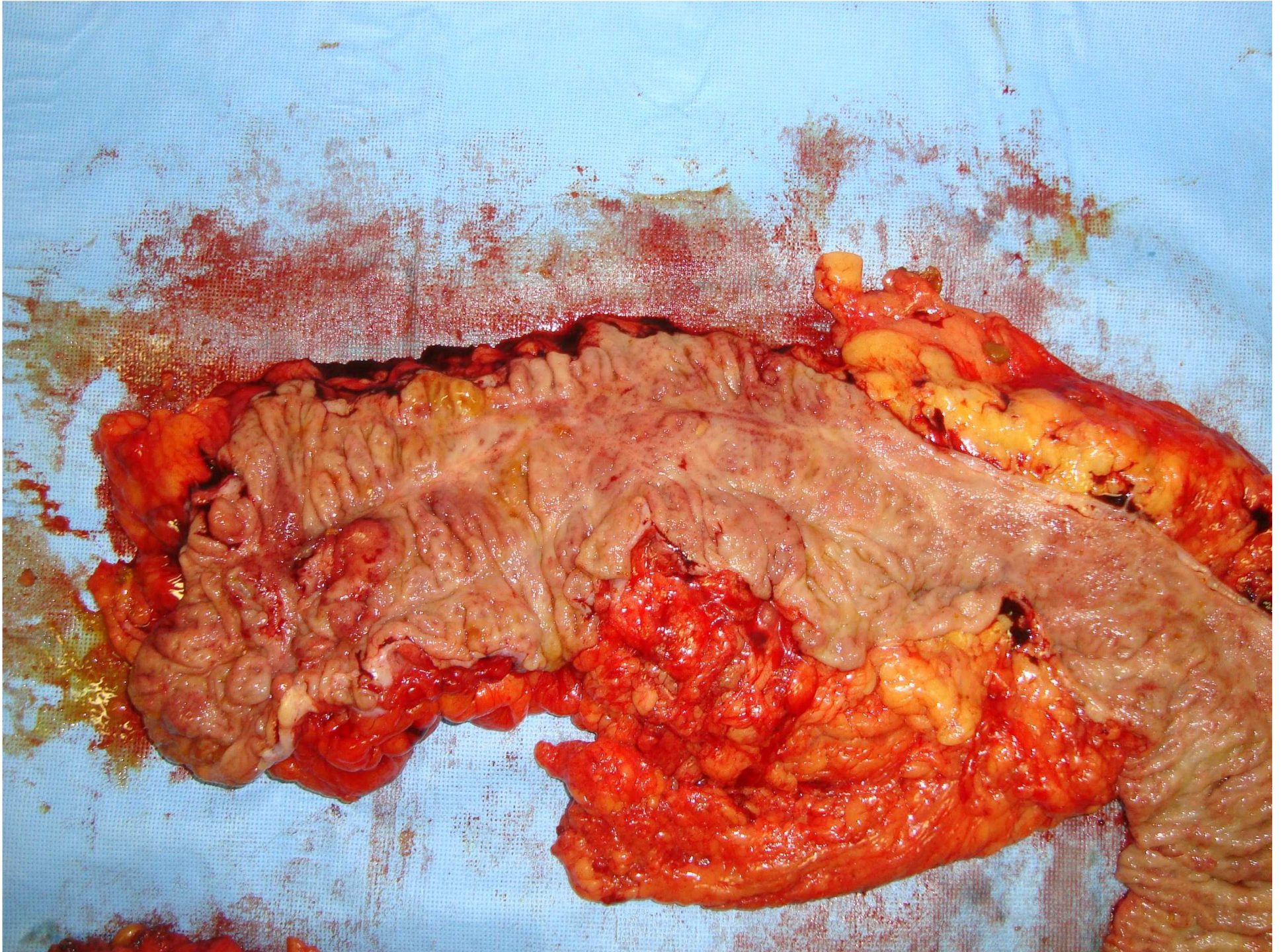
TABLE 4. Treatment of Dysplasia in IBD

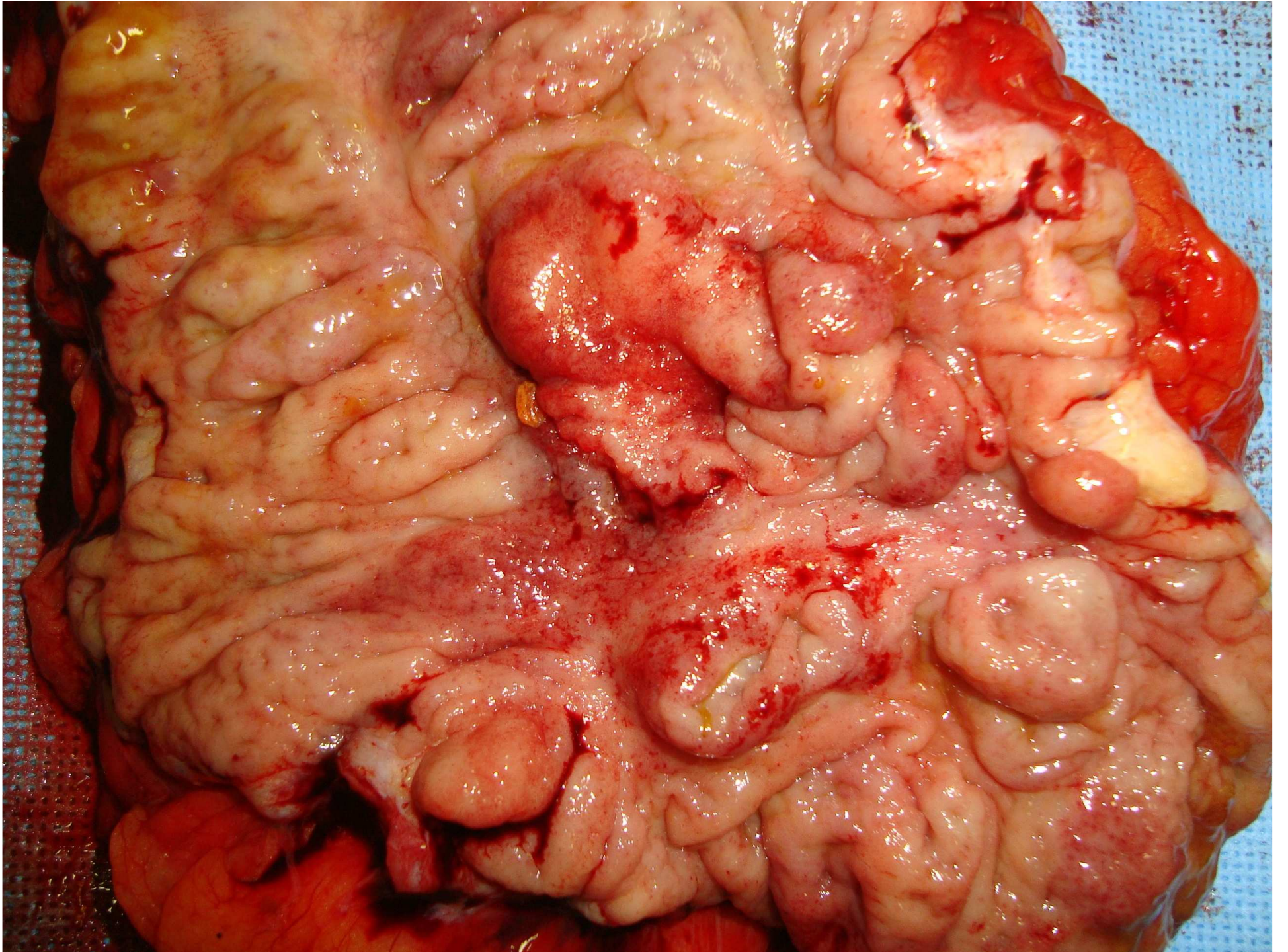


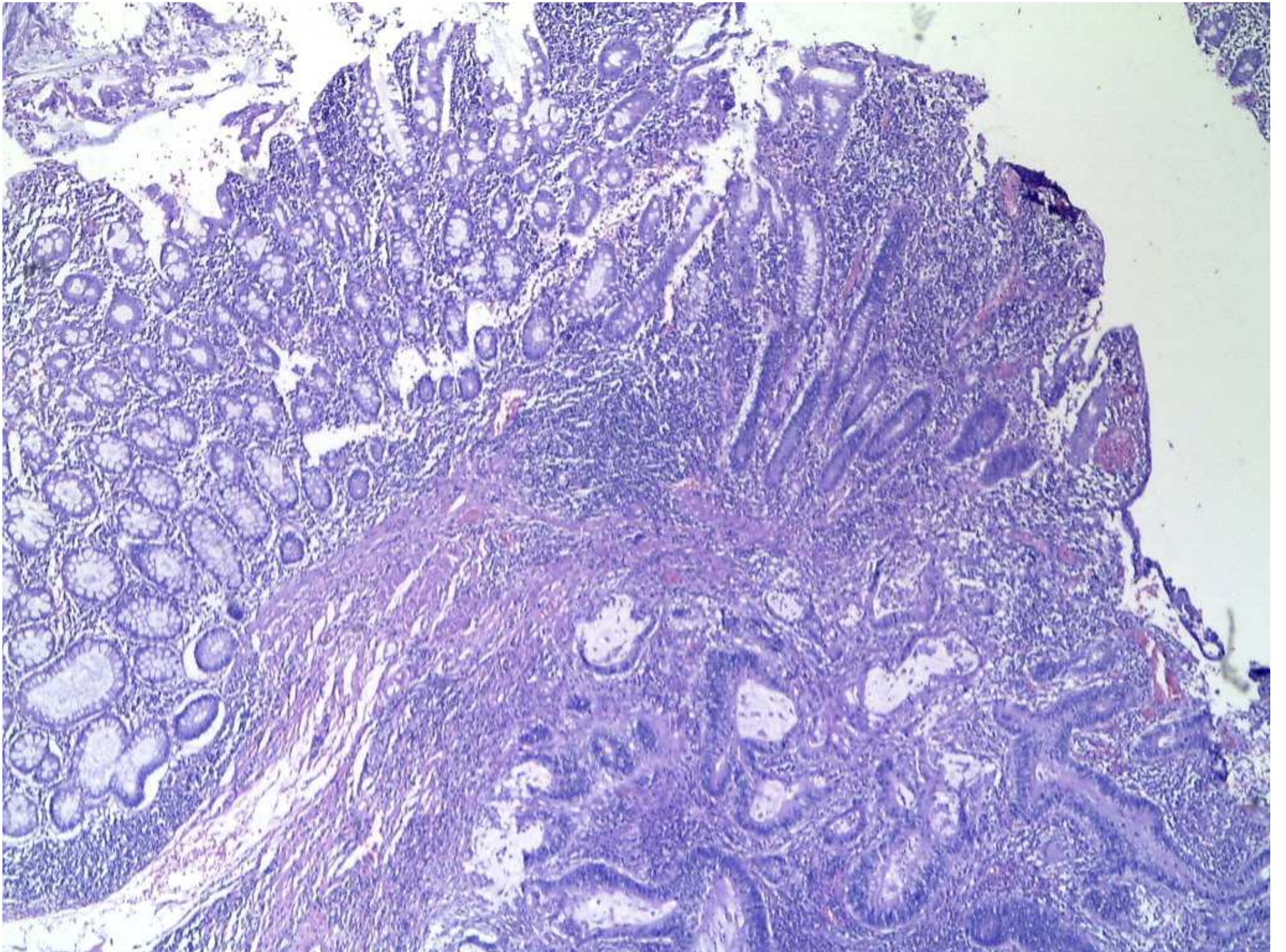
* Polyp implies benign dysplastic epithelium, well circumscribed, completely excised, and not associated with either flat dysplasia or carcinoma.

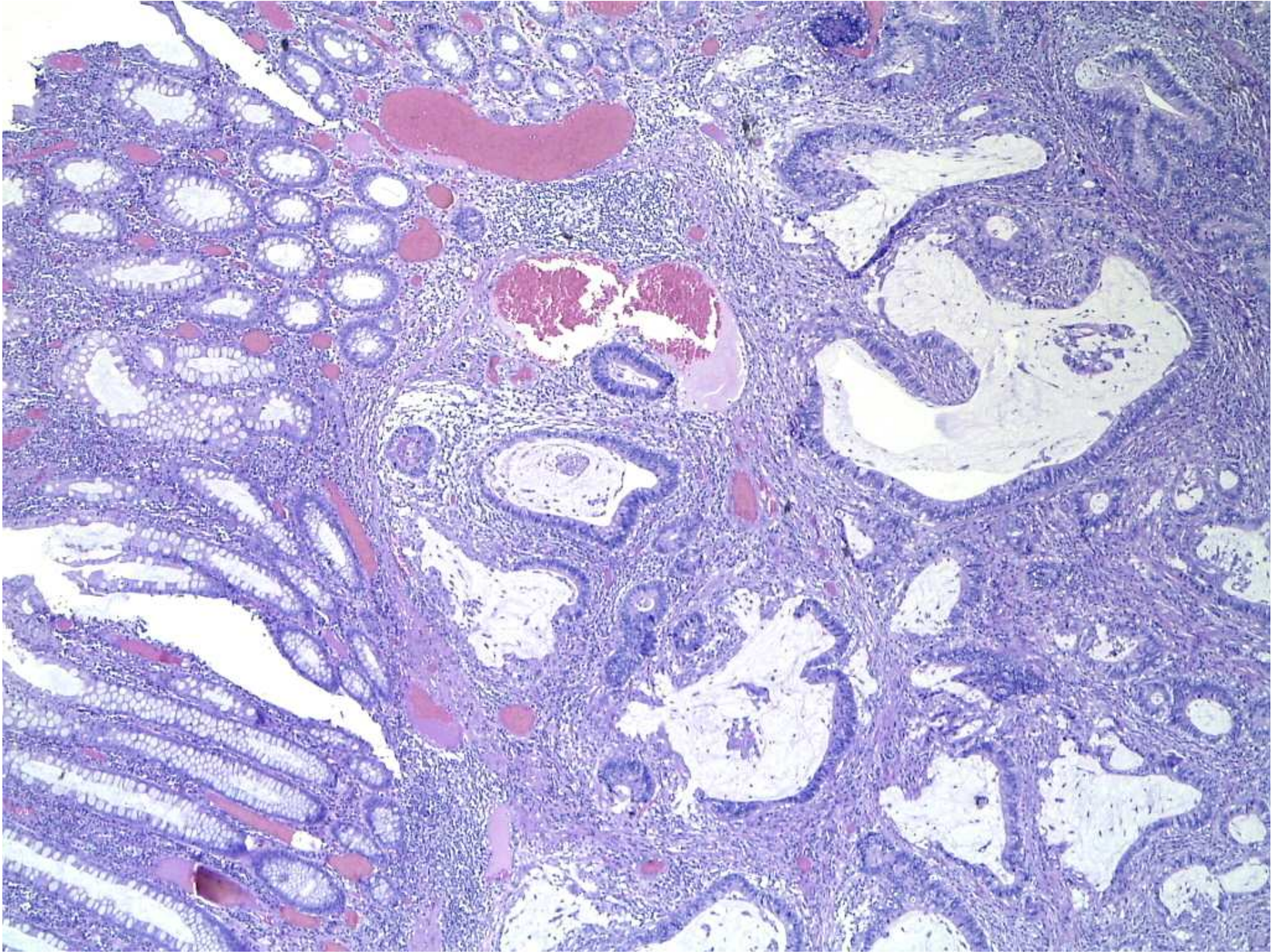


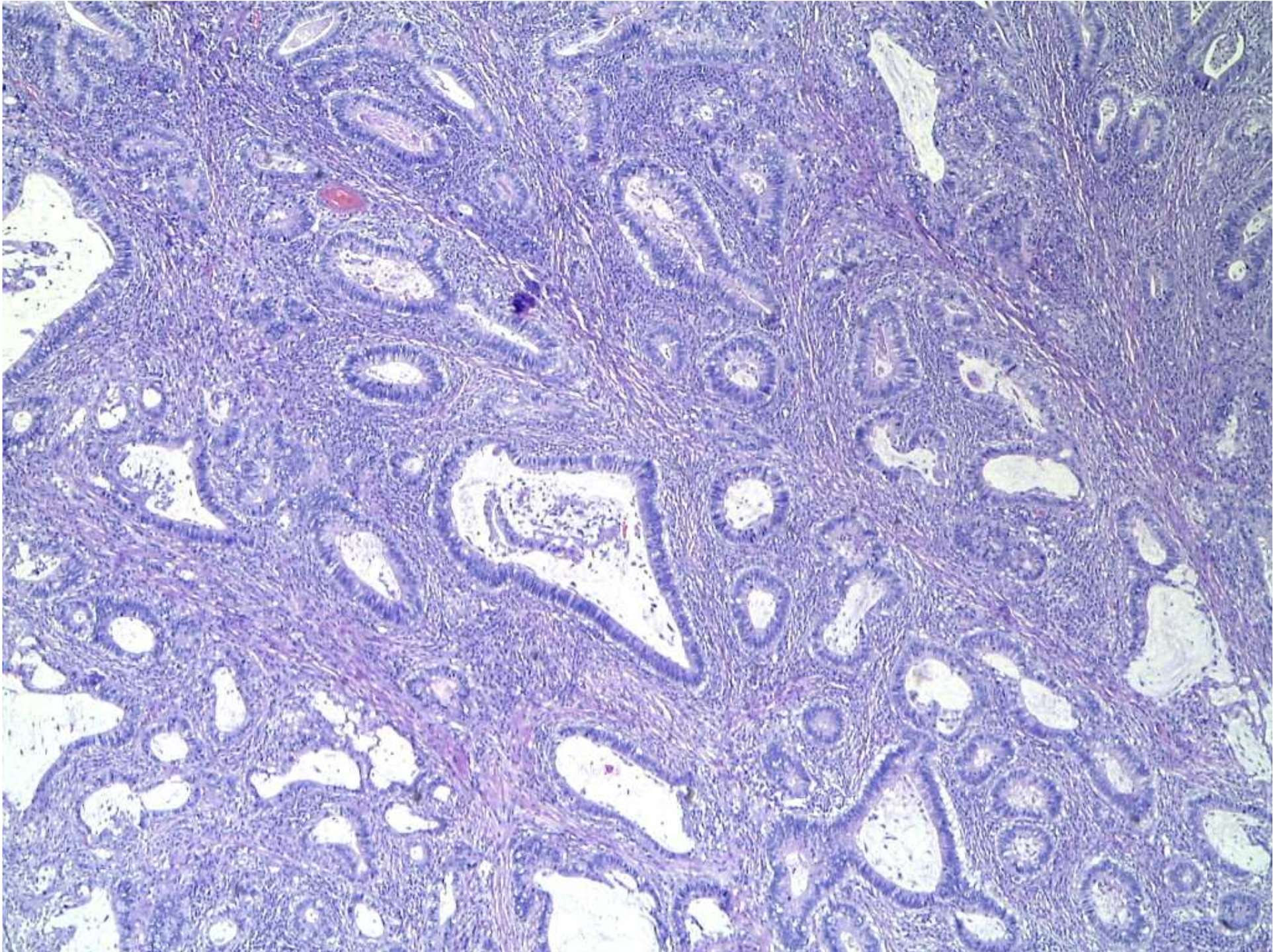


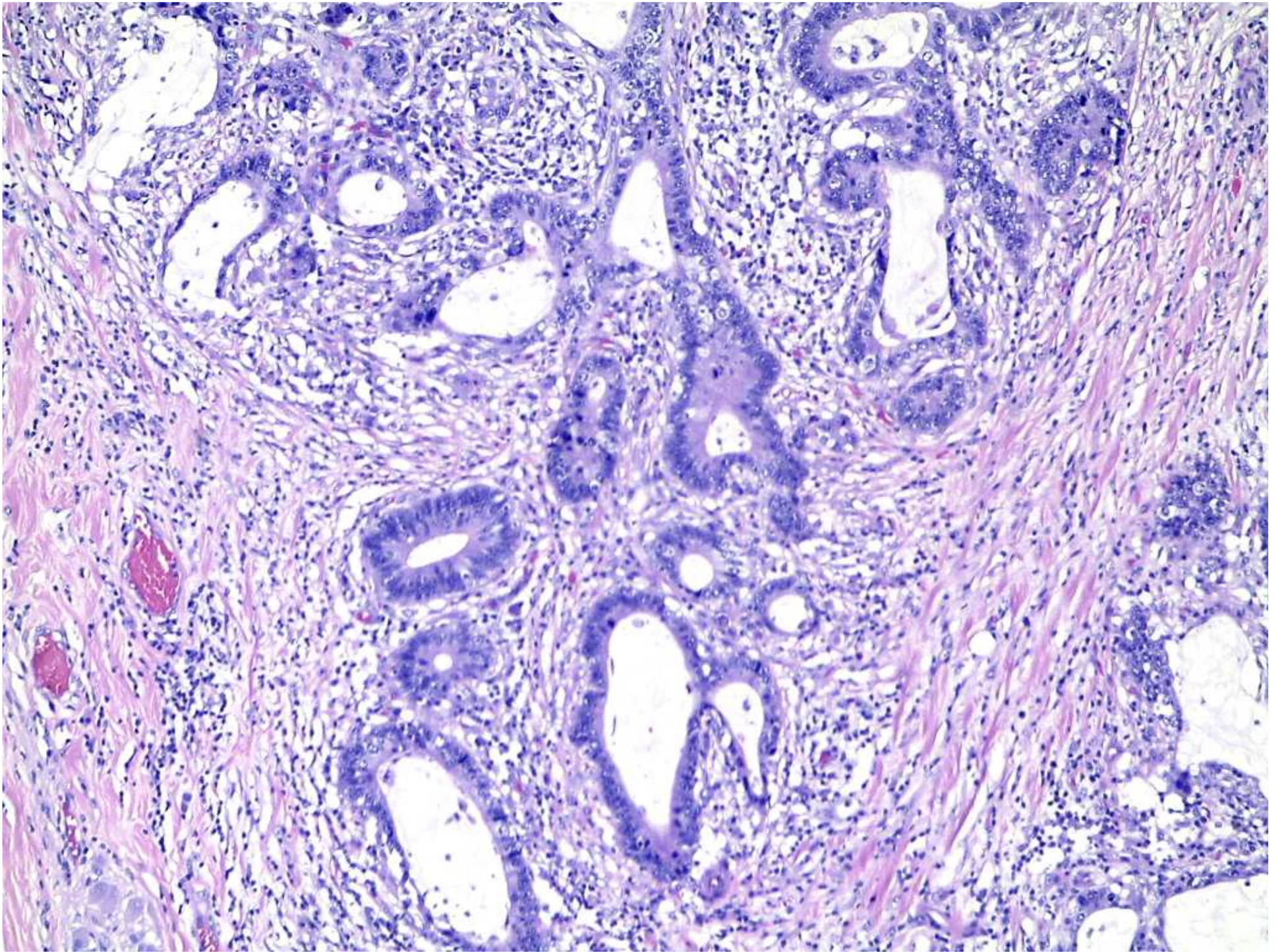


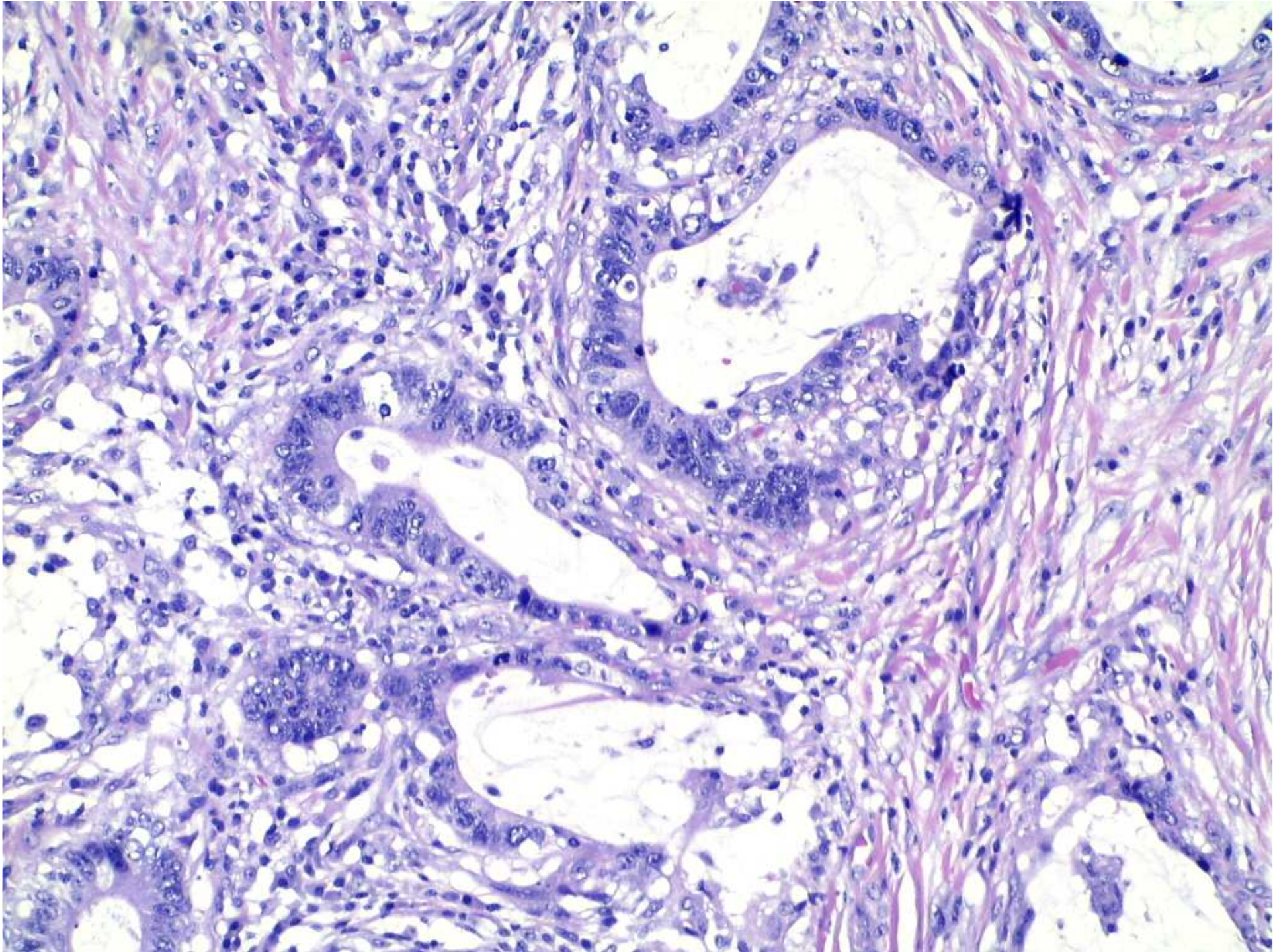


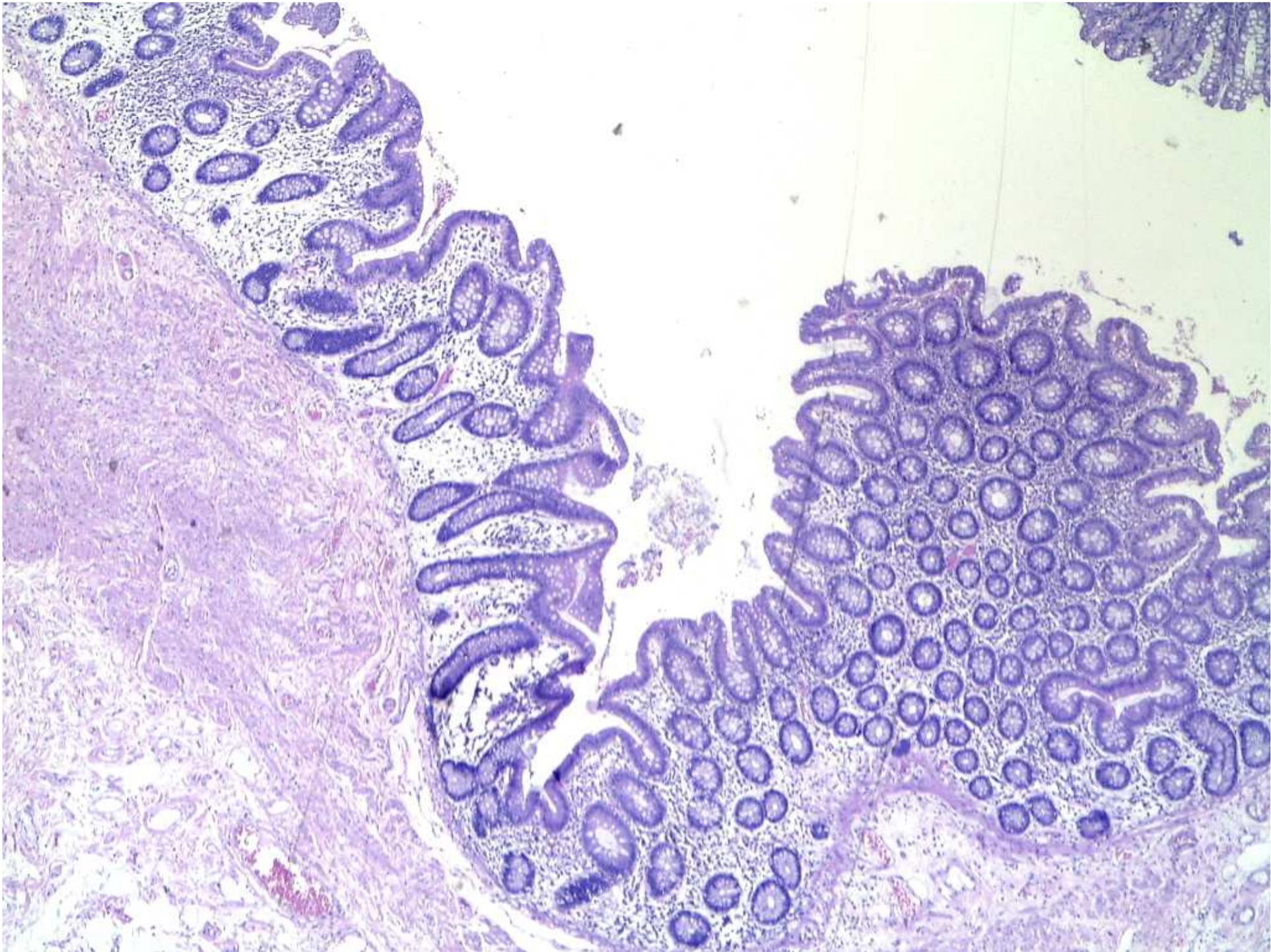


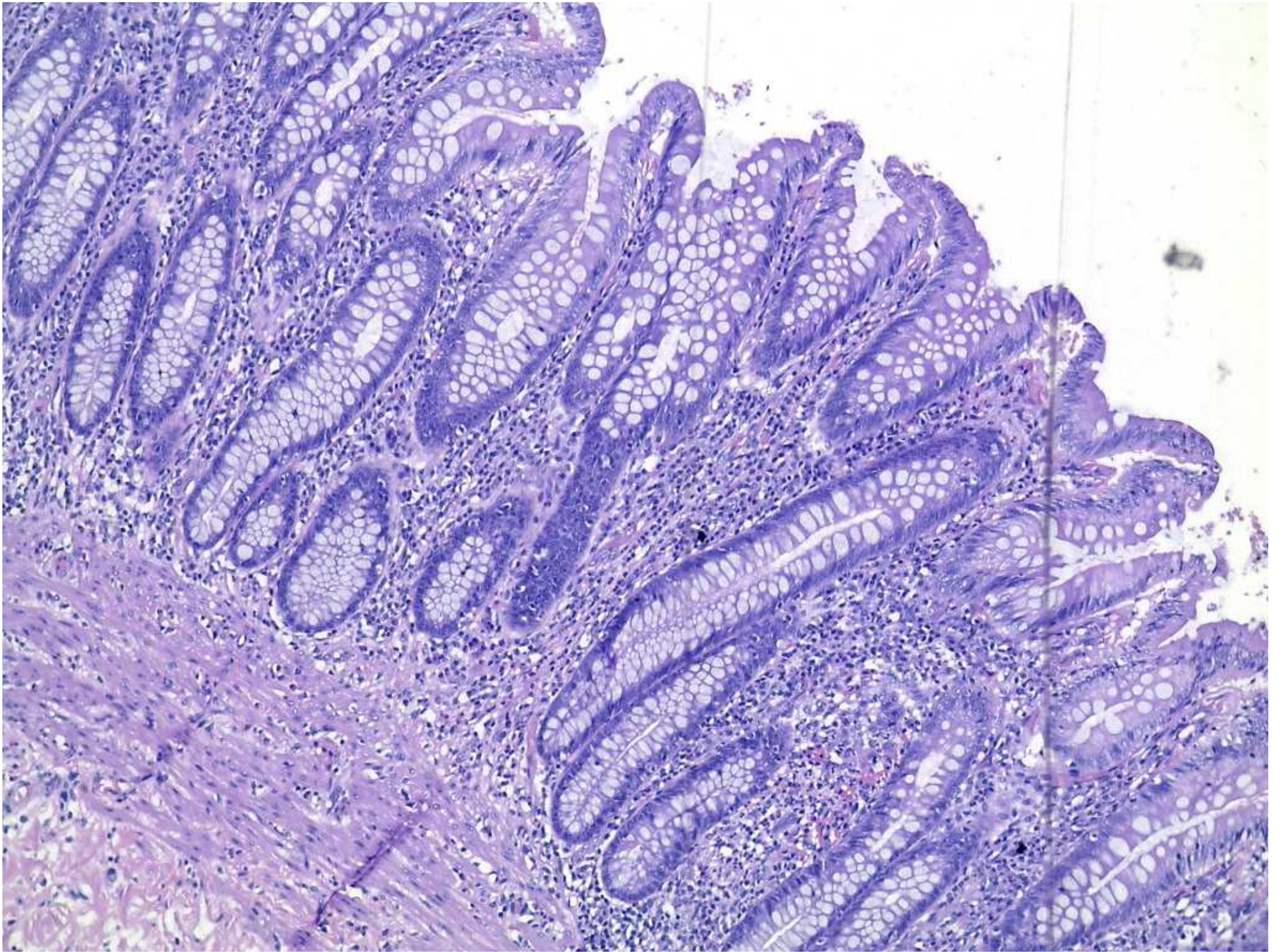




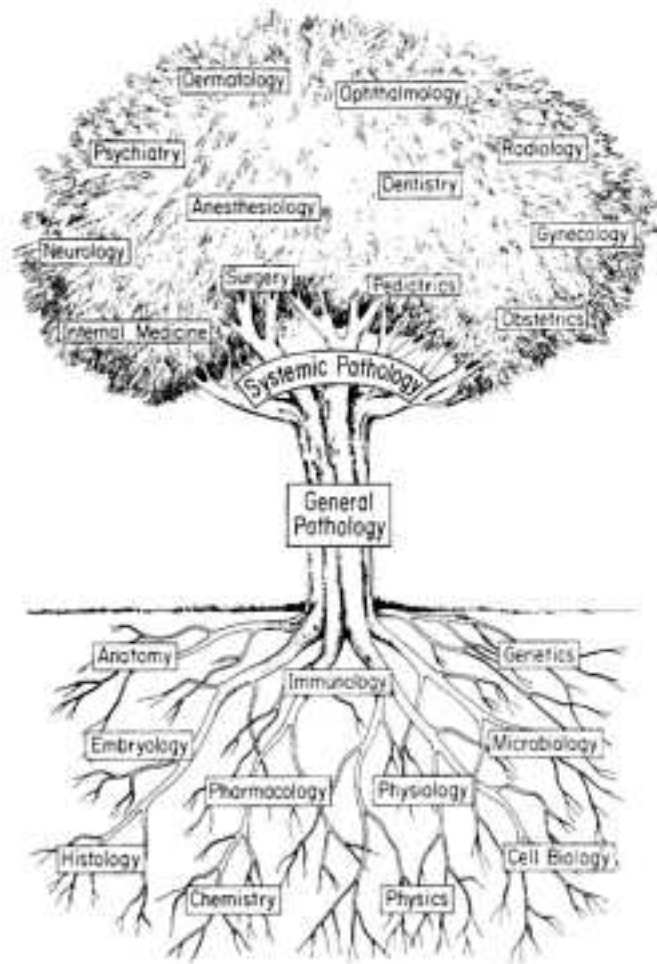








THE TREE OF MEDICINE



After George Th. Diamandopoulos

Rizoma

