



Sociedade Brasileira de Patologia



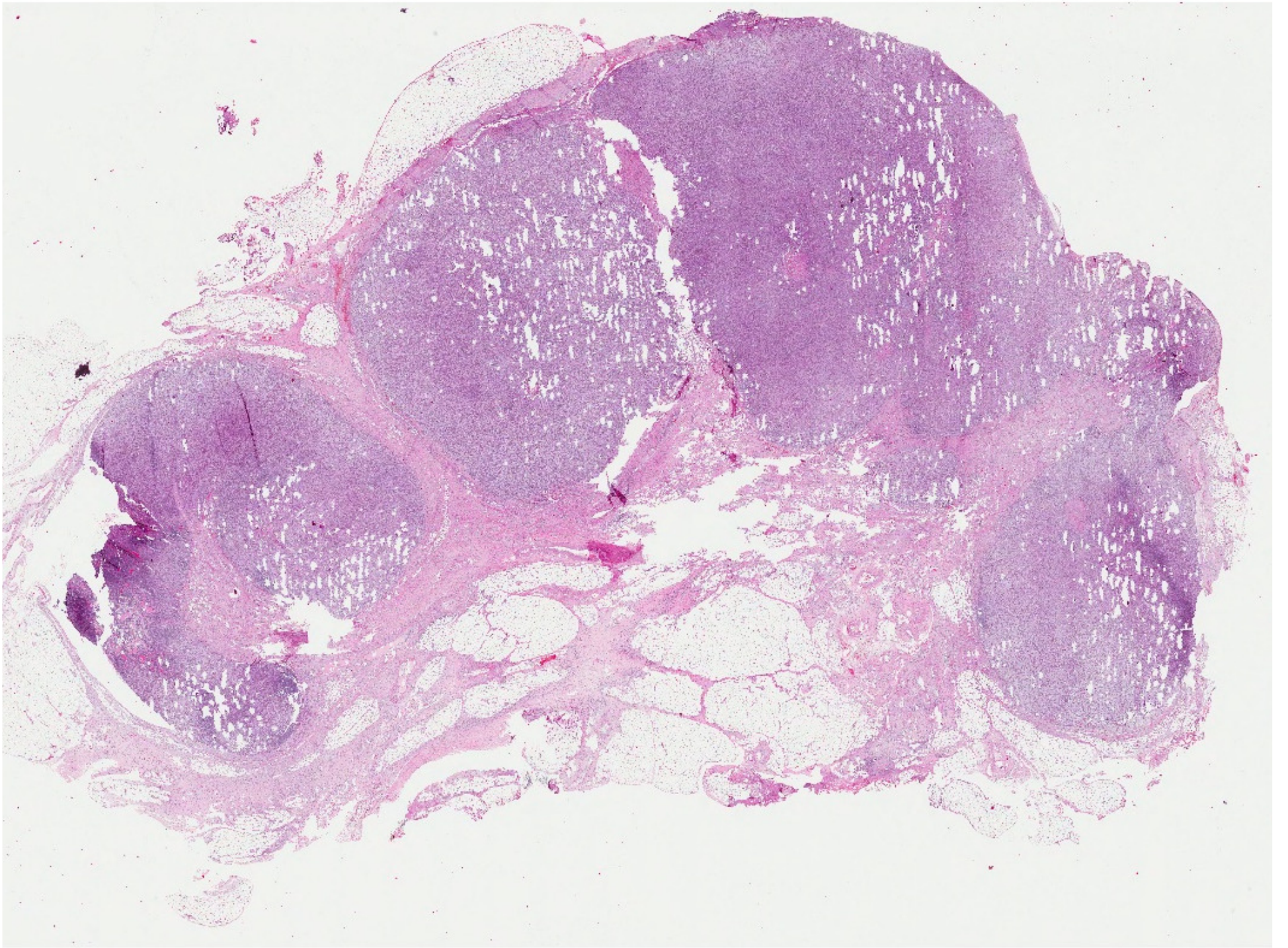
Caso do mês

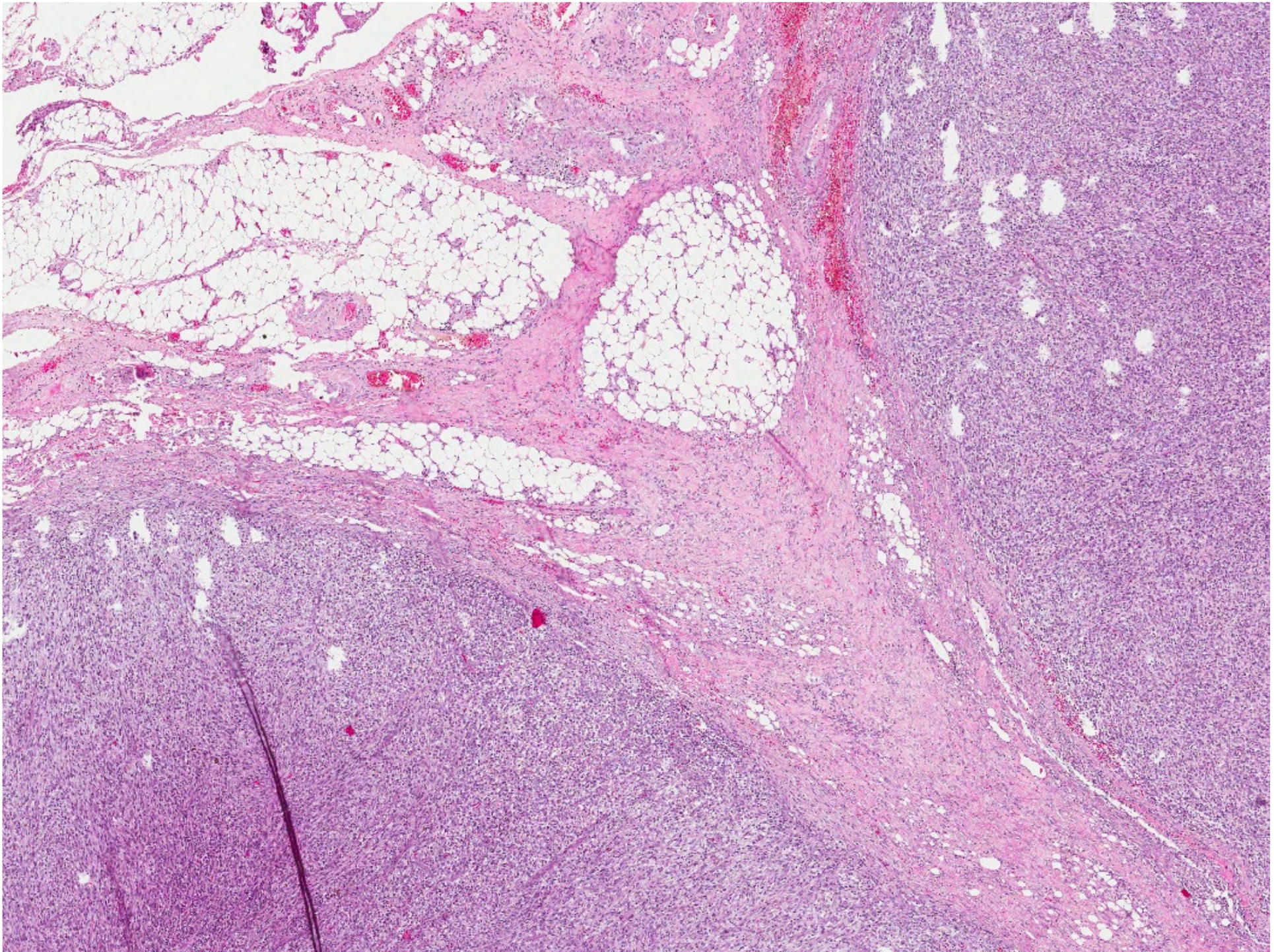
Américo Delgado Brilhante
Felipe D'Almeida Costa
Departamento de Anatomia Patológica

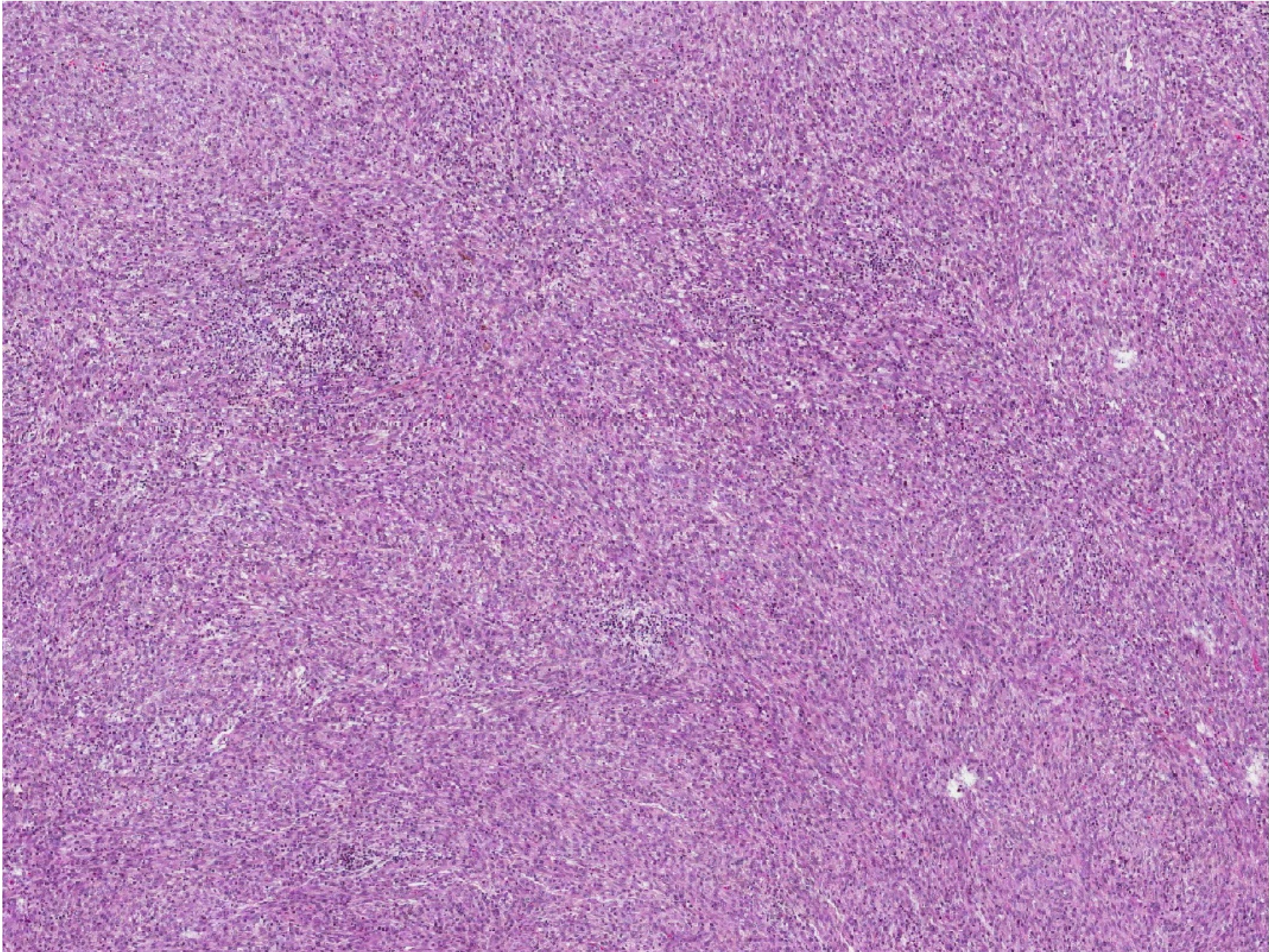


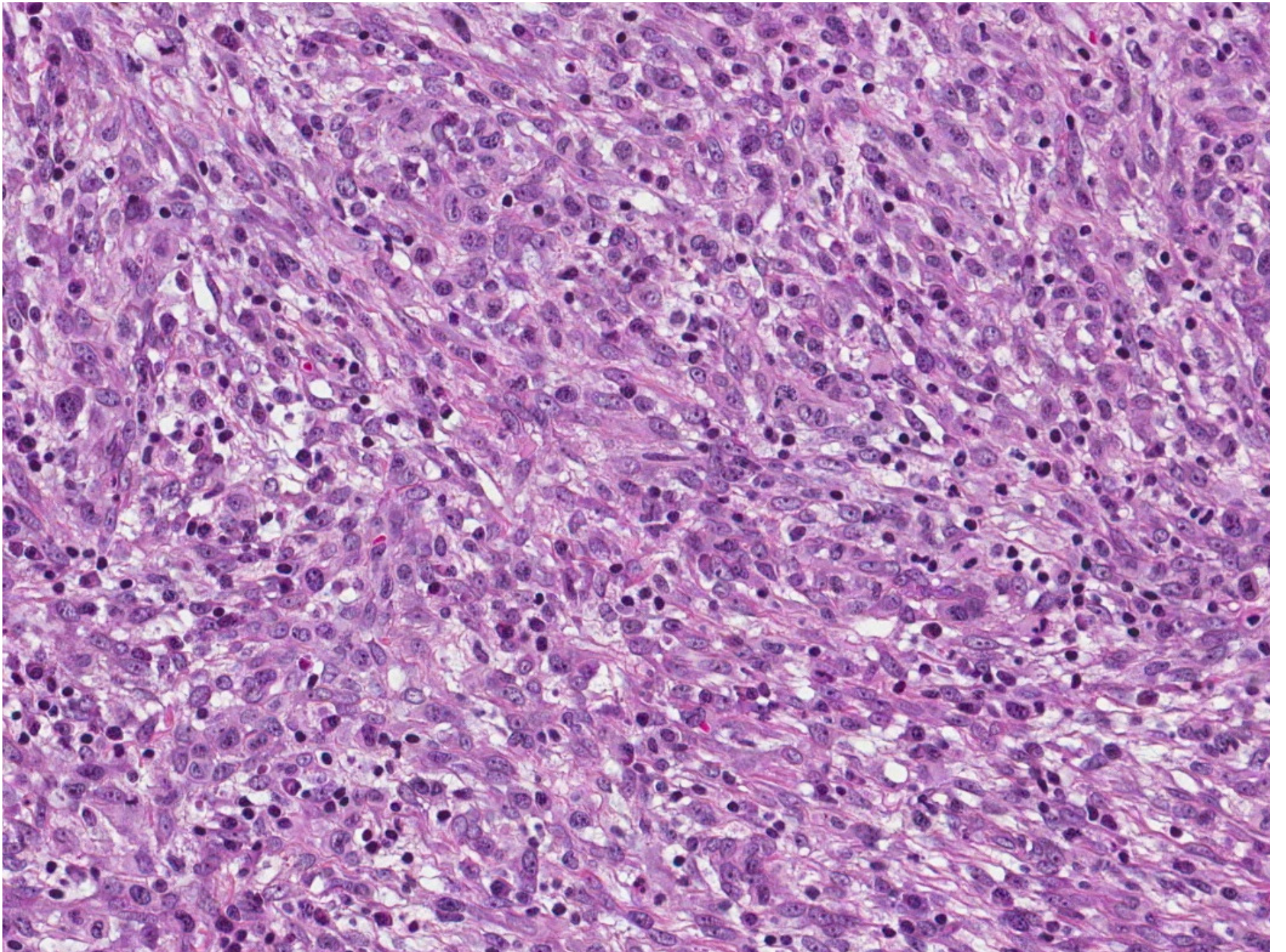
A.C. Camargo
Cancer Center

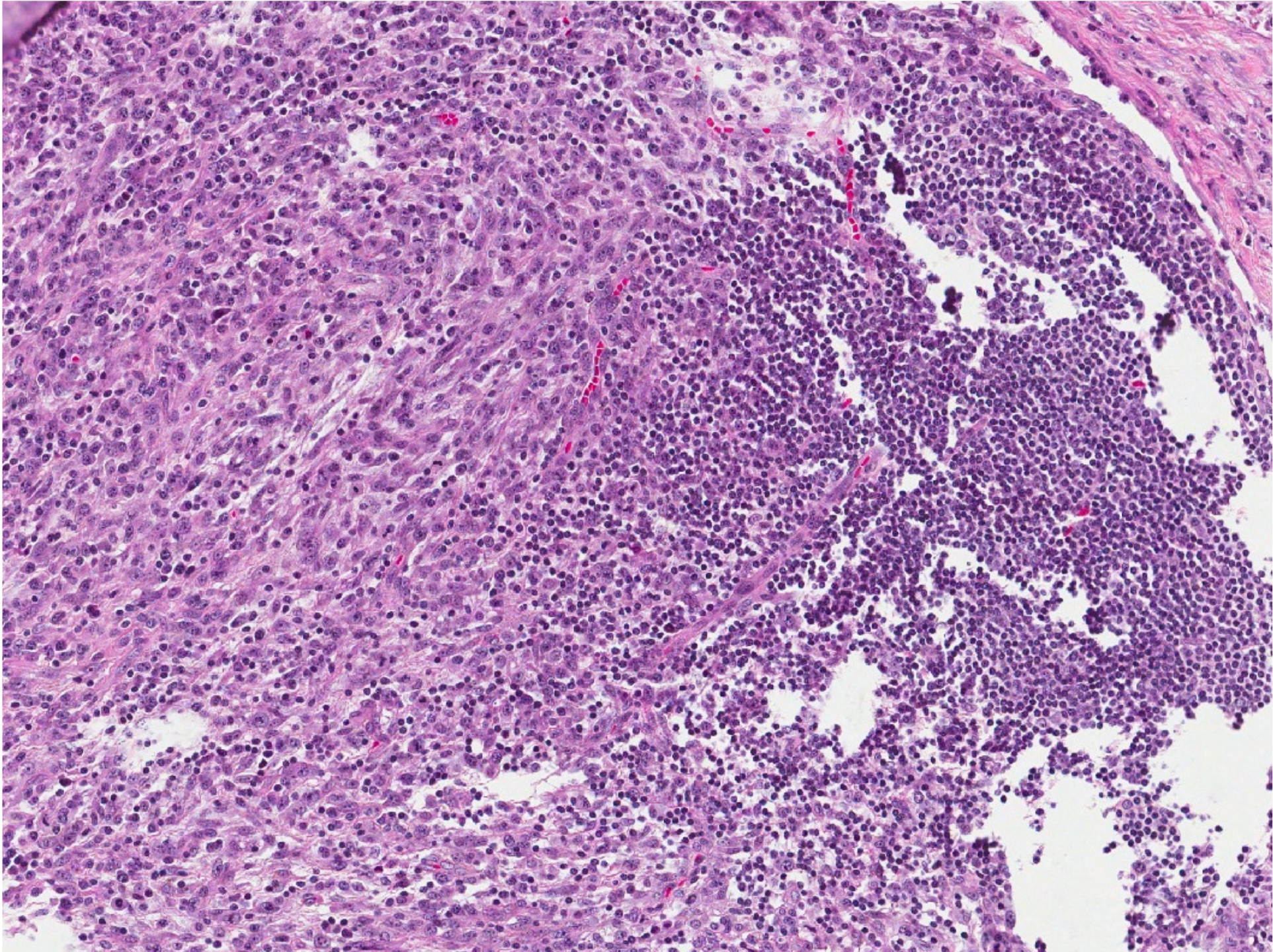
- Homem, 55 anos
- Dor e abaulamento em região inguinal esquerda
- Febre vespertina há 30 dias
- TC de abdômen: linfadenomegalias inguinais e ilíacas externas à esquerda
- TC de tórax e marcadores tumorais: normais
- Realizou biópsia excisional de um nódulo

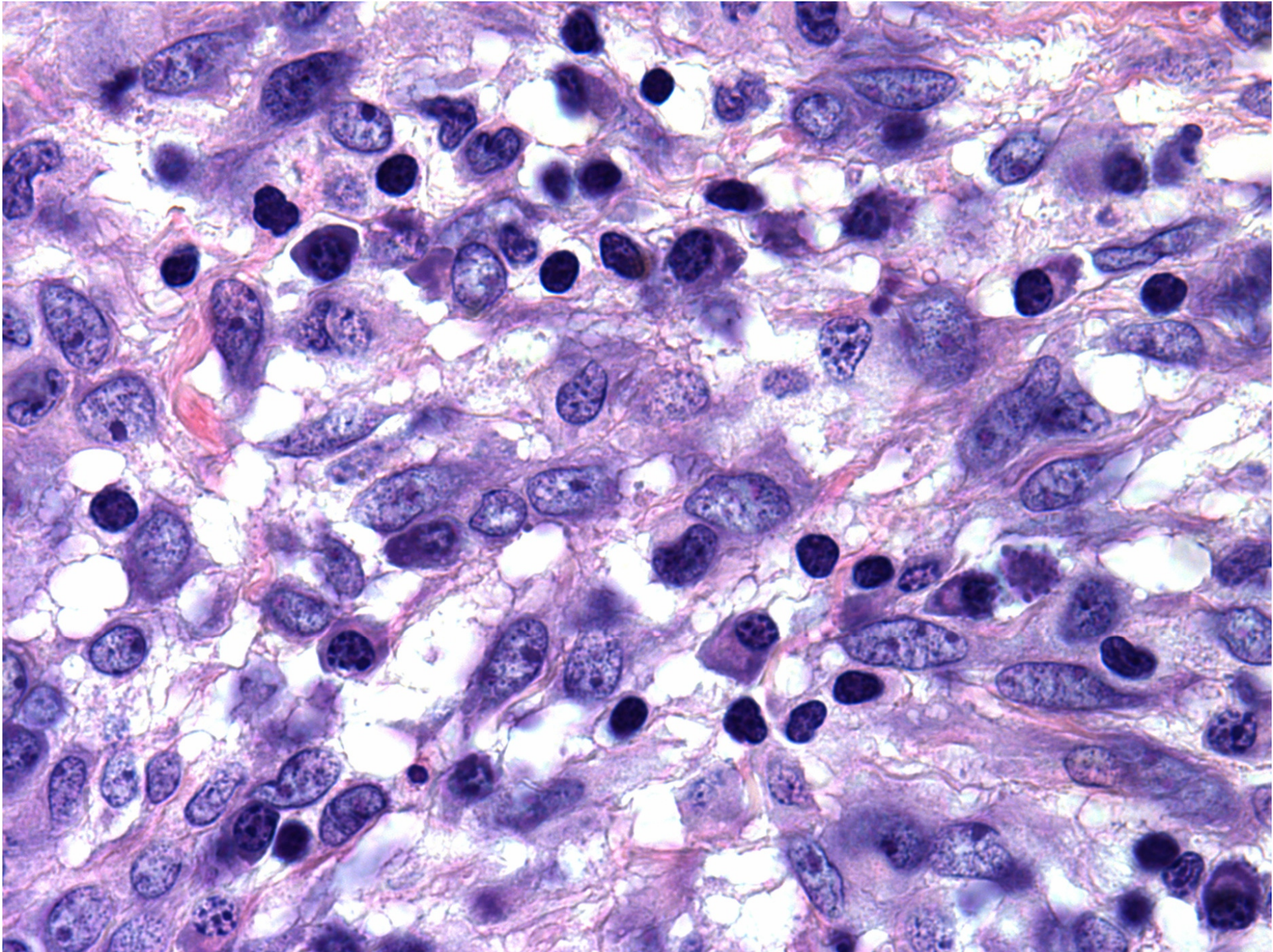














A.C. Camargo
Cancer Center



Sociedade Brasileira de Patologia

**Com base nos achados
morfológicos, qual o seu
diagnóstico?**